

# The Effects of Pharyngeal Flap Surgery on Lateral Pharyngeal Wall Motion: A Videoradiographic Evaluation

MICHAEL B. LEWIS, M.D.  
HERMINE M. PASHAYAN, M.D.

*Boston, Massachusetts 02111*

Twenty patients undergoing *pharyngeal flap surgery* to correct *velopharyngeal incompetence* were studied by *speech videofluoroscopy* pre- and postoperatively to determine the effects of the surgical procedure on *lateral pharyngeal wall motion*. Within the limits of clinical judgment and for purposes of surgical planning, the motion was not altered. The implications of this are discussed.

## Introduction

The role of lateral pharyngeal wall motion in velopharyngeal closure, especially in the cleft palate patient, has been recognized for years (Astley, 1958; Griffith, et al., 1968; Skolnick, 1969). Multiview videofluoroscopy has allowed a much better understanding of the velopharyngeal sphincter and has demonstrated the variabilities in closure or attempted closure depending on the relative contributions of the velum and lateral pharyngeal walls (Skolnick, et al., 1973).

How the information gained from multiview videofluoroscopy can be used in the surgical management of patients with velopharyngeal incompetence is not clear. The posterior pharyngeal flap, the most commonly used surgical procedure to correct velopharyngeal incompetence, has for the most part been used empirically, functioning at least partially as a tissue obturator. Isshiki (1969) first theorized that the width of the flap or the size of the lateral apertures to be formed should be decided upon with due consideration of the mobility of the lateral pharyngeal walls. The possibility that pharyngeal flap surgery could

alter lateral pharyngeal motion has not been investigated. Clinical evidence would suggest that lateral pharyngeal wall motion is not greatly affected, as those patients who have good lateral pharyngeal wall motion preoperatively usually obtain the best results after pharyngeal flap surgery (Kelsey et al., 1972). However this has not conclusively been demonstrated.

The purpose of this study is to determine the effects of the superiorly based pharyngeal flap operation on lateral pharyngeal wall motion as seen on speech videofluoroscopy.

Although large numbers of patients with velopharyngeal incompetence and pharyngeal flap surgery have been studied and reported, only one group of patients has been reported in which videofluoroscopic assessment of lateral pharyngeal wall motion has been done both before and after flap surgery (McCall et al., 1975).

## Methods

Twenty patients with velopharyngeal incompetence following cleft palate repair were studied with speech videofluoroscopy both before and at least six months after a superiorly based pharyngeal flap was performed. Dilute barium was used for contrast. Lateral, frontal, and basal views were obtained. A high resolution cesium iodide image amplifier tube of 6" diameter with a Plumbicon television and Conrac T.V. monitor and a Sony videotape recorder were used.

Because an extra videofluoroscopic examination

---

The authors are affiliated with the Boston Floating Hospital, Tufts-New England Medical Center Hospital, 171 Harrison Avenue, Boston, Massachusetts 02111. Dr. Lewis is Chief of Plastic Surgery, Division of Plastic Surgery and Dr. Pashayan is in the Department of Pediatrics.

This material was presented at the 35th Annual American Cleft Palate Association Meeting in Atlanta, Georgia, April 3-8, 1978.

was required on each child, there was concern about the radiation risk to the thyroid gland. Before doing repeat studies, the dose of radiation to the skin over the thyroid gland was measured in a different group of 13 patients. The dose was consistently less than 1 rad, and this was thought to be low enough that the exam could be repeated without undue danger (Foster, 1975).

The posterior pharyngeal flaps were all superiorly based and were described as moderately wide to wide in the operative note. Several different techniques of lining and lateral port control were used, and four different surgeons were involved.

Lateral pharyngeal wall motion was determined on frontal view and was graded from 1 to 5 (Figure 1). Three was midway between the resting position and the radiographic center of the pharynx. Motion was assessed during connected speech. In addition, in the post-flap study, the level of maximum lateral pharyngeal wall motion relative to the flap position was determined on frontal view (Figure 2), i.e., was the flap above, below or at the same level as maximum lateral pharyngeal motion?

## Results

The results are summarized in Table 1. In two patients, postoperative lateral pharyngeal wall motion exceeded preoperative motion.

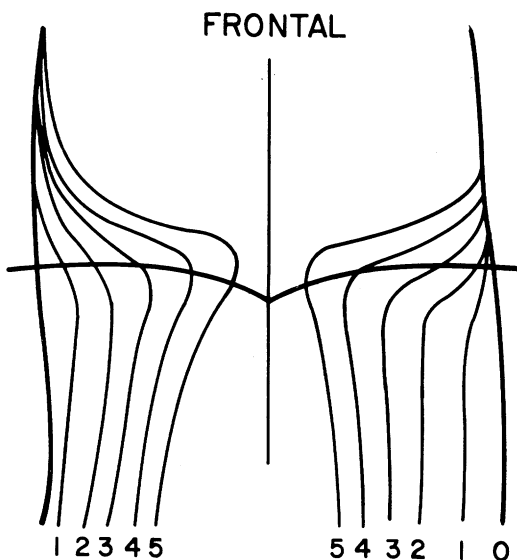


FIGURE 1. Diagrammatic scheme for the grading of lateral pharyngeal wall motion as seen on frontal view.

Fifteen were thought to be unchanged. In three cases, postoperative motion was judged to be slightly less, but in each of these medial motion of the lateral pharyngeal walls appeared to be impeded by the bulk of the pharyngeal flap.

Flap position, relative to maximum lateral pharyngeal wall motion was low in eleven cases, the same in nine. In no instance was the flap judged to be above the point of maximum lateral pharyngeal wall motion.

## Discussion

Although Isshiki (1969), more than ten years ago, suggested that the width of the posterior pharyngeal flap should be determined after first considering the mobility of the lateral pharyngeal wall, it was only recently that the accuracy of this thought was tested (Argamaso, et al., 1978). Furthermore, there is nothing in print to demonstrate that the lateral pharyngeal wall motion noted preoperatively would not be altered by the surgical procedure itself although McCall et al. (1975) presented a paper on this subject.

There is no consensus as to which muscle or combination of muscles is responsible for lateral pharyngeal wall motion. Based on anatomical studies, Dickson (1972) has postulated that the levator veli palatini is responsible for lateral pharyngeal wall motion as well as velar elevation. Others (Strong, 1949; Bloomer, 1953) have suggested that the superior pharyngeal constrictor and palatal-pharyngeus produce the inward movement of the pharyngeal walls. Even the salpingopharyngeus (Calnan, 1955) has been suggested as playing a role. Innervation of these muscles is through the pharyngeal plexus with contributions from cranial nerves IX, X, and possibly VII (Nishio, et al., 1976).

Conceivably, the surgical procedure of raising the pharyngeal flap (which includes pharyngeal muscle tissue as well as mucosa) could alter lateral pharyngeal wall motion. If it did, Isshiki's hypothesis could be incorrect.

This study demonstrates that, within the limits of clinical observation, the degree of lateral pharyngeal wall motion is not significantly altered by the pharyngeal flap operative procedure. In the three cases in which lateral pharyngeal wall motion was judged to be less, the bulk of the flap itself appeared to

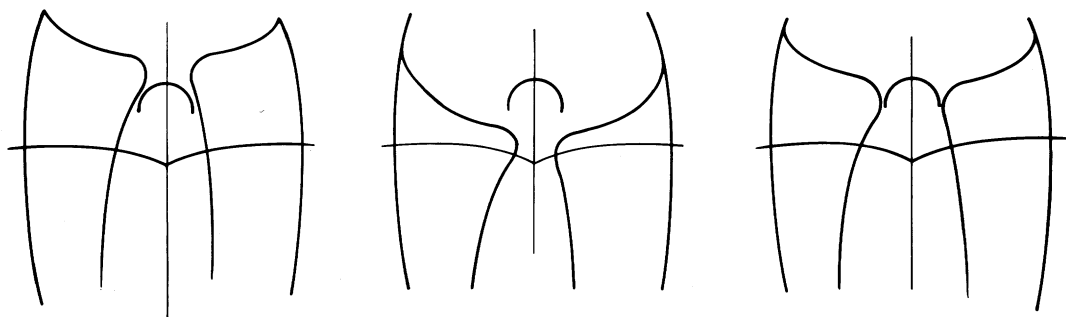


FIGURE 2. Diagrammatic demonstration of the pharyngeal flap being below (left), above (center), and at the same level (right) as maximum lateral pharyngeal wall motion as seen on frontal view.

TABLE 1. Summary of Results

Patient	LPW* Motion Pre-Flap	LPW Motion Post Flap	Flap Position Relative to Maximum LPW Motion
M.B.	4	4	Low
B.M.	4	4	Low
M.C.	4	3**	Same
J.H.	4	3**	Same
L.O.	4	3**	Same
S.J.	3	3	Same
M.C.	3	3	Low
M.G.	3	3	Low
B.C.	3	3	Low
C.E.	3	3	Same
M.S.	3	3	Low
S.K.	3	3	Low
J.K.	3	3	Same
H.M.	3	3	Same
T.K.	3	3	Low
M.W.	2	2	Same
E.W.	2	2	Low
K.W.	2	2	Low
A.C.	2	3	Same
P.S.	1	2	Low

\* Lateral Pharyngeal Wall

\*\* LPW Movement Impeded by Flap

be inhibiting medial motion of the lateral pharyngeal walls. For purposes of surgical planning, motion observed preoperatively on videofluoroscopy can be relied upon to remain following the surgery.

Although speculative, this knowledge should allow the surgeon to alter flap width and lateral port caliber as originally suggested by Isshiki. This in turn might prevent some of the problems related to very small lateral ports by allowing the surgeon to create a narrower flap in those individuals with good lateral pharyngeal wall motion. The problems

related to small lateral ports include de-nasal voice quality, mouth breathing, the "hang jaw" look due to mouth breathing, possible hyper-eruption of teeth, disturbance in nasal physiology and most important and fortunately least common, obstructive airway problems.

Robson (1977) Jackson (1976) have described acute or dramatic chronic cases of airway obstruction related to pharyngeal flap. Ogura (1966) feels there is a fundamental relationship between the degree of nasal obstruction and pulmonary function, which, in its worst form can lead to cor pulmonale.

Beyond this is a more subtle form of airway obstruction which occurs during sleep and has recently been emphasized (Guilleminault et al., 1977). Sleep disorders, snoring, sleep apnea, daytime sleepiness, mental dullness, bed-wetting, nightmares and behavior problems have all been described secondary to this condition. Simmons (1976) has recently reviewed this problem and described 44 children and adults with this problem. Although none of them had had pharyngeal flaps, one can imagine that, if enlarged tonsils or adenoids could cause this problem, certainly a wide pharyngeal flap could. Recently, just such a case was reported (Borowiecki, et al., 1978). Certainly most would agree that the wider the lateral ports and the less the nasal obstruction, consistent with velopharyngeal closure, the better off the patient is.

Vertical malpositioning of pharyngeal flaps as a cause of persistent velopharyngeal incompetence has been described (Skolnick, 1972). If lateral pharyngeal wall motion is to be maximally utilized, the pharyngeal flap must be positioned at the level of greatest motion.

In only nine of the patients studied was this the case. In eleven, the pharyngeal flap was thought to be too low. In none was it too high. For this reason, the technique described by Owsley (1966) of the high attached pharyngeal flap would seem to be the preferred method for performing a pharyngeal flap. Greater attention to complete lining of the pharyngeal flap might also aid in controlling vertical position of the flap as it relates to maximum lateral pharyngeal wall motion.

## Conclusions

Twenty patients undergoing pharyngeal flap surgery to correct velopharyngeal incompetence were studied by speech videofluoroscopy pre- and postoperatively to determine the effects of the surgical procedure on lateral pharyngeal wall motion. Within the limits of clinical judgment and for purposes of surgical planning, the motion was not altered. The implications of this are discussed.

## References

- ARGAMASO, R., SHPRINTZEN, R., CROFT, C., and DANILLER, A., Surgical variation of postoperative pharyngeal flap width: A method for matching the flap to the gap, American Cleft Palate Association Meeting, Atlanta, Georgia, 1978.
- ASTLEY, R., The movements of the lateral walls of the nasopharynx: A cineradiographic study, *J. Laryng. and Otol.*, 72, 325-332, 1958.
- BLOOMER, H., Observations on palatopharyngeal movements in speech and deglutition, *J. Speech and Hear. Res.*, 18, 231-239, 1953.
- BOROWIECKI, B., POLLAK, C., and CROFT, C., Sleep apnea hypersomnia syndrome following pharyngeal flap surgery, American Cleft Palate Association Meeting, Atlanta, Georgia, 1978.
- CALNAN, J., Movements of the soft palate, *Speech*, 154, 14-20, 1955.
- DICKSON, D., DICKSON, W., Velopharyngeal anatomy, *J. of Speech and Hear. Res.*, 15, 372-381, 1972.
- FOSTER, R., Thyroid irradiation and carcinogenesis, *Am. J. of Surg.*, 130, 608-611, 1975.
- GRIFFITH, B., MONROE, C., HILL, B., WALDROP, W., and WHITE, H., Motion of the lateral pharyngeal walls during velopharyngeal closure, *Plast. and Reconst. Surg.*, 41, 338-347, 1968.
- GUILLEMINAULT, C., ELDRIDGE, F., TILKIAN, A., and SIMMONS, B., Sleep apnea syndrome due to upper airway obstruction, *Arch. Intern. Med.*, 137, 296-300, 1977.
- ISSHIKI, N., HONJOW, I., and MORIMOTO, M., Cineradiographic analysis of movement of the lateral pharyngeal wall, *Plast. and Reconst. Surg.*, 44, 357-363, 1969.
- JACKSON, P., WHITAKER, L., and RANDALL, P., Airway hazards associated with pharyngeal flaps in patients with the Pierre Robin Syndrome, *Plast. and Reconst. Surg.*, 58, 184-186, 1976.
- KELSEY, C., EWANOWSKI, S., CRUMMY, A., and BLESS, P., Lateral pharyngeal wall motion as a predictor of surgical success in velopharyngeal insufficiency, *New Eng. J. of Med.*, 287, 64-68, 1972.
- MCCALL, G. N., SKOLNICK, M. L., SHPRINTZEN, R. J., and CASPER, J., Changes in lateral pharyngeal wall movement after pharyngeal flap surgery: A preliminary investigation, American Cleft Palate Association Annual Meeting, February 26-March 1, 1975, not yet in press.
- NISHIO, J., MATSUYA, T., IBUKI, K., and MIYAZAKI, T., Roles of the facial, glossopharyngeal and vagus nerves in velopharyngeal movement, *Cleft Palate J.*, 13, 201-213, 1976.
- OGURA, J., Nasal obstruction and the mechanics of breathing, *Arch. Otolaryng.*, 83, 77-84, 1966.
- OWSLEY, J., LAWSON, L., MILLER, E., and BLACKFIELD, H., Experience with the high attached pharyngeal flap, *Plast. and Reconst. Surg.*, 38, 234-242, 1966.
- ROBSON, M., STANKIEWICZ, J., EDSTROM, L., and MENDELSON, J., Cor pulmonale secondary to cleft palate repair, *Plast. and Reconst. Surg.*, 59, 754-757, 1977.
- SIMMONS, F., GUILLEMINAULT, C., DEMENT, W., and TILKIA, A., Surgical management of airway obstruction during sleep, *Laryng.*, 94, 326-338, 1976.
- SKOLNICK, M., Videovelopharyngography in patients with nasal speech, with emphasis on lateral pharyngeal wall motion in velopharyngeal closure, *Radiology*, 83, 747-755, 1969.
- SKOLNICK, M., MCCALL, G., Velopharyngeal competence and incompetence following pharyngeal flap surgery: Videofluoroscopic study in multiple projections, *Cleft Palate J.*, 9, 1-12, 1972.
- SKOLNICK, M., MCCALL, G., BARNES, M., The sphincteric mechanism of velopharyngeal closure, *Cleft Palate J.*, 10, 286-305, 1973.
- STRONG, L., Muscle force components in the occlusive mechanism of the nasopharynx, *Anat. Rec.*, 106, 510-522, 1949.