

Review of Diastrophic Dwarfism Associated with Cleft Palate—Presentation of a Case

NICHOLAS HERR, M.D.

DICRAN GOULIAN, JR., M.D., D.D.S.

New York, New York 10021

Diastrophic Dwarfism, a rare syndrome first described by Lamy and Maroteaux in 1960 (1) has not received adequate exposure in the plastic surgical literature. Of the 121 cases reported to date in the world literature, practically all have been in the orthopedic, radiographic or pediatric journals. This paper will serve to familiarize the plastic surgeon with only the main aspects of this disease entity; for more details, the interested reader is referred to the excellent review by Walker *et al.* (3).

Diagnosis is usually made during the neonatal period. The infant displays a typical combination of dwarfism and shortened extremities (Figure 1), almost always associated with severe bilateral clubbing of the feet and characteristic deformities of the hands which are almost pathognomic of the disease. In the differential diagnosis diastrophic dwarfism is most frequently confused with achondroplasia.

Once past infancy, the prognosis for survival is good. Infant mortality is due to respiratory problems, usually pneumonia, and particularly aspiration pneumonia. Intelligence is unimpaired.

Diastrophic dwarfism is one of the inheritable disorders of connective tissue (2) and like achondroplasia appears to be an inborn error of chondrogenesis. However, the histological pattern is entirely different from that seen in achondroplasia. It is thought to be inherited as an autosomal recessive which makes the differential diagnosis between achondroplasia and diastrophic dwarfism mandatory as achondroplasia is inherited as an autosomal dominant.

Unfortunately, very little in the way of corrective surgery can be offered to the patient as far as the major defects are concerned. Scoliosis, though not present at birth, becomes progressive and severe. The clubbed feet are notoriously resistant to orthopedic intervention and compounded by associated dislocations and deterioration of the hip joints (3). The hand deformities (Figure 2) while striking are not debilitating and the patient usually learns to write well with a pincer grip between the index

The authors are affiliated with the Department of Surgery, Division of Plastic Surgery, The New York Hospital, Cornell University Medical Center, New York, New York.

Presented at the 31st Annual Meeting of the American Cleft Palate Association, May 12, 1973, Oklahoma City, Oklahoma.

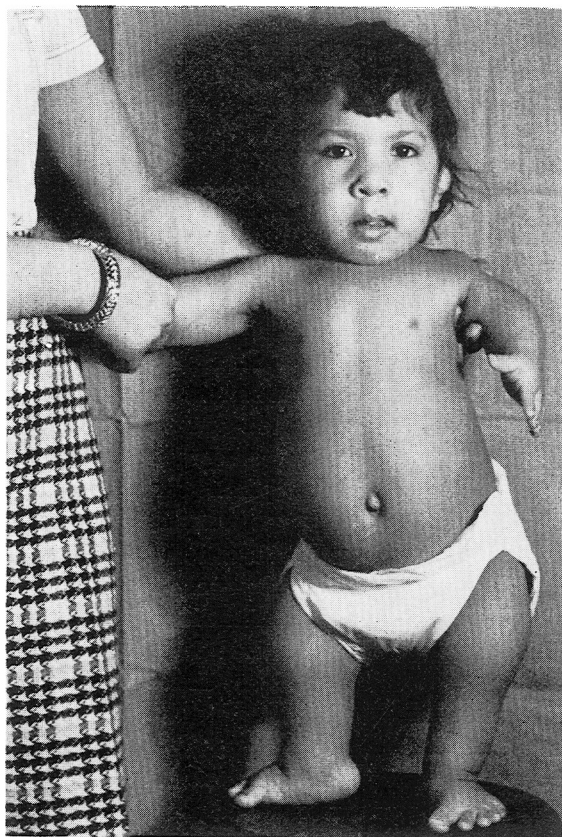


FIGURE 1. M.B. being held by her mother. Note shortened long bones and typical facies.

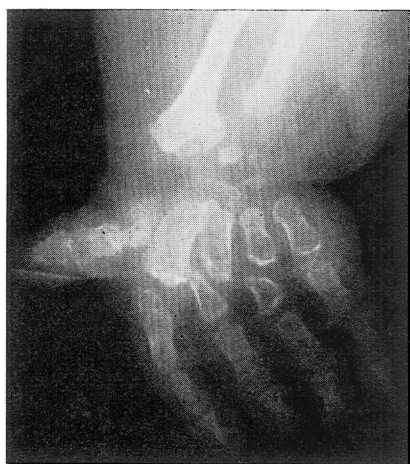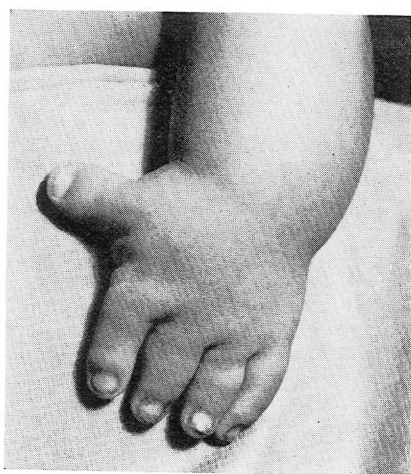


FIGURE 2A. Close up of left hand. Note characteristic "hitch-hiker" thumb. B. Radiograph of left hand.

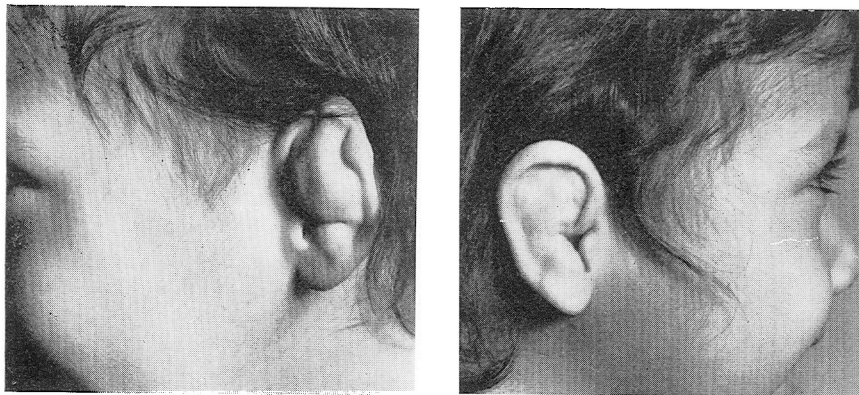


FIGURE 3. Close ups of (L) and (R) external pinnae.

and middle fingers. The external ear deformities (Figure 3) are confined to the ear lobes and occur following an inflammatory process in the ear lobes. Hearing is not usually affected.

Of interest to the plastic surgeon is the fact that abnormalities of the palate are frequent and range from a high arched palate to partial or complete palatal clefts (3). The incidence of cleft palates ranges up to 59%. Because, as mentioned previously, these children have normal intelligence it is important that corrective surgery be offered for amenable palatal lesions. A word of caution is appropriate here regarding the kyphosis of the cervical spine which may be present in these children along with abnormalities of the cervical vertebrae themselves (3). Radiographs allow visualization of the spine and help alert the physician that some problem may be present. Also, abnormalities of the larynx and trachea do occur infrequently (3) and should be sought for prior to attempts at intubation.

Case Presentation

M.B. was born to a 22 year old mother. She was misdiagnosed as having achondroplastic dwarfism at birth. At age 2 months she was correctly diagnosed at another plastic surgery clinic. Closure of the soft palate was attempted at age 13 months and was only partially successful (Figure 4). Bilateral myringotomies were performed at this time. At age 15 months she was first seen by our orthopedic colleagues at the Hospital for Special Surgery where in May, 1972, she underwent bilateral tendoachilles lengthening as the beginning of a program to make the child eventually ambulatory.

In August, 1972, at age 2½ years she was admitted to the Plastic Surgery Service of The New York Hospital for closure of her cleft palate.

Upon this admission she weighed 10.6 kg. and was 70 cm. in height (3 percentile). Her general appearance can be appreciated in Figure 1. Note

the shortened long bones and characteristic facies. The narrow bridge of the nose gives the illusion that the eyes are abnormally spaced, which they are not. The mid-nose is broad and flat with flaring nostrils. Fullness of the lower lip is another characteristic of this form of dwarfism.

Figure 2A is a close up to demonstrate the "hitch-hiker" thumb which is due to the associated short malformed first metacarpal bone. Figure 2B shows the radiographs of this hand. Figure 3 demonstrates the external ear deformities, which in this case are bilateral but not symmetrical. The palatal defect, which was quite broad, is well demonstrated in Figure 4. The defect was successfully closed surgically. Figure 5 is a 6 month follow-up view. Although she is just beginning to talk, her mother states she notices a marked progressive improvement in the child's speech. At present she still cannot walk unassisted, but continues on a gait training program and may eventually require further orthopedic surgery.

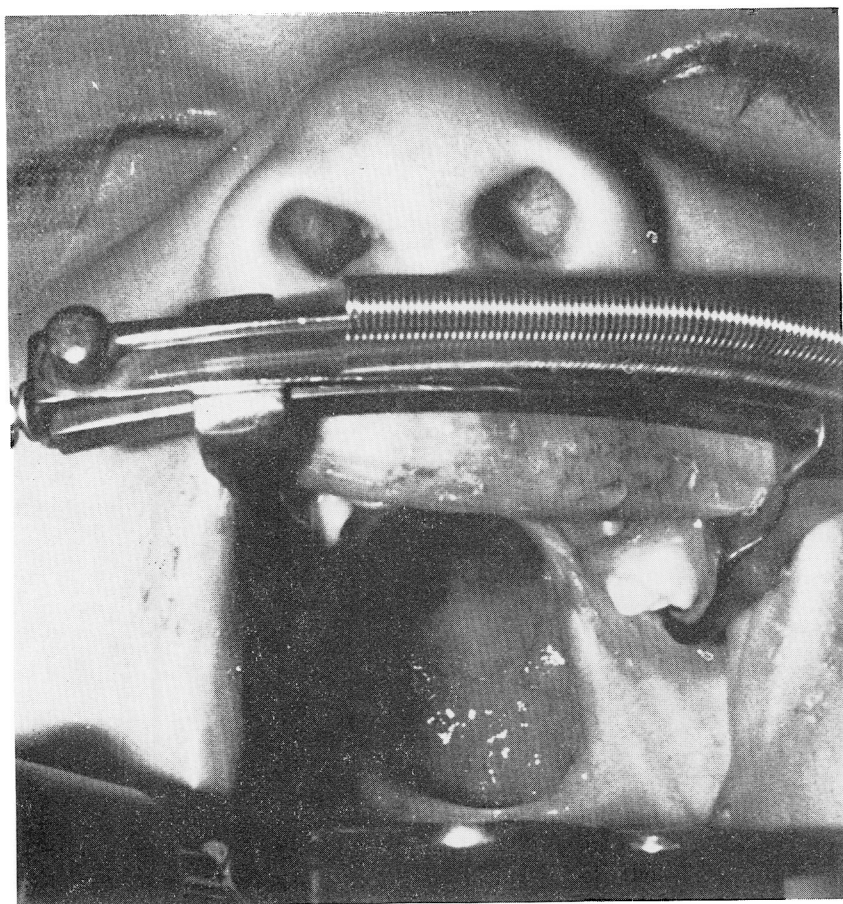


FIGURE 4. Pre-op intra-oral view of palatal defect. Note partial soft palate closure from prior operation.

Summary

A case presentation of diastrophic dwarfism is presented to familiarize the plastic surgeon with this rare syndrome which once having "been seen" is easy to recognize. No other form of bony dysplasia exhibits the combination of deformities which characterize this syndrome. Our patient illustrates all of the "classical stigmata" of diastrophic dwarfism including large residual palatal defect following attempted prior soft palate closure. The patient recently underwent successful closure of the cleft palate.

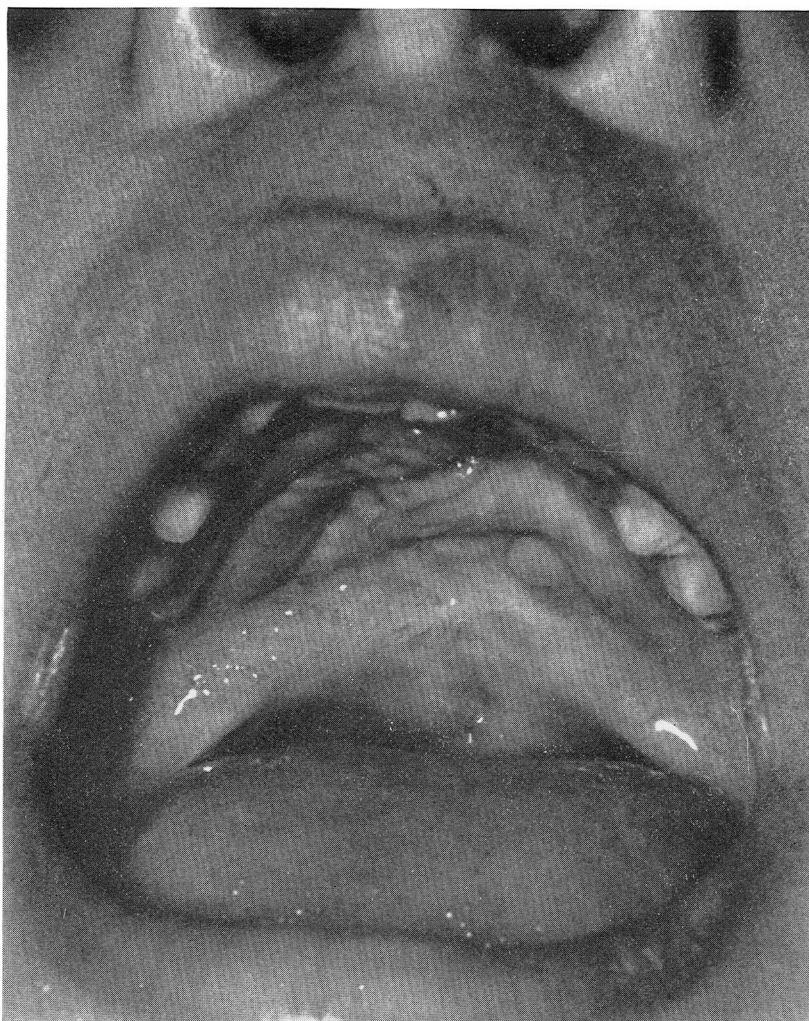

FIGURE 5. Intra-oral view of palate 6 months following successful surgical closure.

References

1. LAMY, M. and MAROTEAUX, P. Le nanisme diastrophique. *Presse Med.* 68, 1977, 1960.
2. McKUSICK, V. A. Heritable Disorders of Connective Tissue, 3rd Ed., C. V. Mosby, Co., p. 464, 1966.
3. WALKER, B. A., SCOTT, C. I., HALL, J. G., MURDOCH, J. L., and McKUSICK, V. A., Diastrophic Dwarfism, *Medicine*, 51, 41, 1972.