

The Modified Striped Y—A Systematic Classification for Cleft Lip and Palate

NABIL I. ELSAHY, M.D., F.R.C.S.(C)

Winnipeg, Manitoba, Canada

The simplest system for recording cleft lip and palate is to present a picture of the condition. Kernahan (2), in 1971 published his excellent paper "The Striped Y—A Symbolic Classification For Cleft Lip and Palate". In this paper he transferred his previous paper (3) "A New Classification For Cleft Lip and Palate" published in 1958, into a symbolic classification.

Conway, et al (1), in 1968 published his article after reviewing 850 cases of cleft lip and palate. They used the Kernahan and Stark classification, but found that they had to add additional subcategories.

Reviewing the charts of patients after using the Striped Y some difficulty was found in recording some of the conditions that do exist.

The urgent need for a uniform system for classification of this difficult problem should encourage writers to improve an already accepted method of classification, especially if it is embryologically based—rather than giving new classifications that do not provide improvement, and may on the contrary, add a lot to the complexity of the problem.

The purpose of my paper is to modify Kernahan's Striped Y by recording more details and thus avoiding the addition of any subcategories. This can be summarized in Figure 1 where:

- Triangle №1 represents the right nostril floor and triangle №5 represents the left nostril floor.
- Square №2 represents the right lip while square №6 represents the left lip.
- Square №3 represents the right alveolus while square №7 represents the left alveolus.
- Square №4 represents the hard palate anterior to the incisive foramen on the right side while square №8 represents the opposite hard palate on the left side. All these structures represent the prepalatal structures.
- The palatal structures are composed of squares №9 and №10 which represent the hard palate and square №11 which represents the soft palate.
- Circle №12 represents the posterior pharyngeal wall while circle №13 represents the premaxilla.

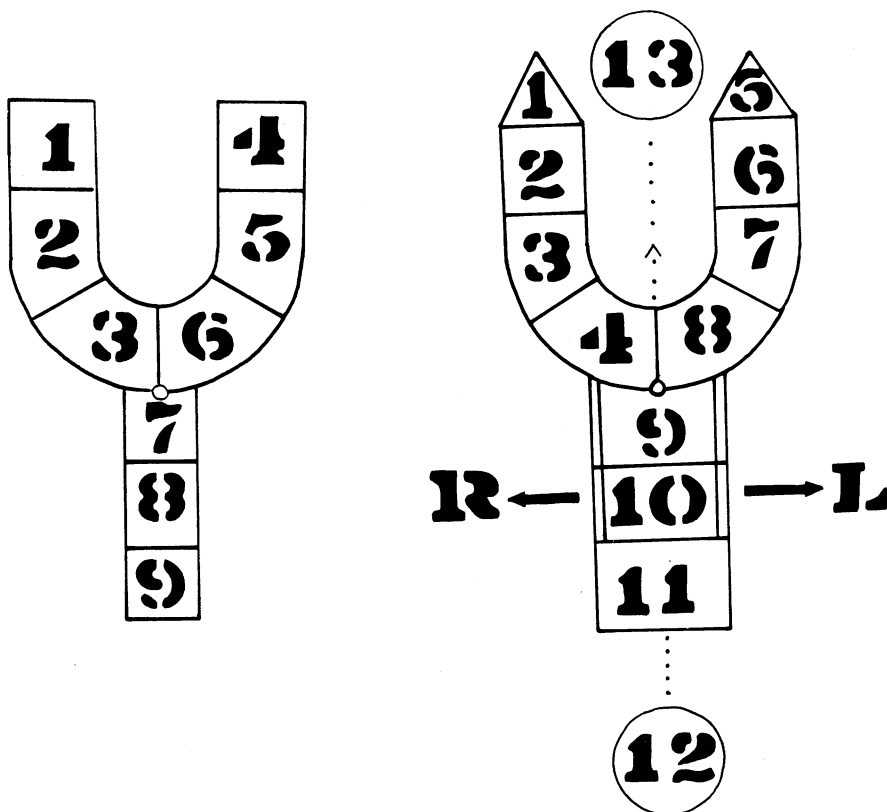


FIGURE 1. Left: The Striped Y: Right: The modified Striped Y.

The modifications can be summarized as follows:

1. In the Striped Y squares, 1 & 4 represent the lip as a whole without differentiation between complete and incomplete cleft lip. In the modified Striped Y, the addition of the triangles 1 & 5 will solve this problem. If the cleft lip is complete, include the nostril floor. The stippling will include both the triangle and the square (1 & 2) or (5 & 6) or both if bilateral. If the cleft lip is incomplete, do not include the nostril floor. The stippling will include only square 2 or 6 or both if bilateral.

2. In the Striped Y there is no description of the state of the alveolus (collapsed or not). In the modified Striped Y, if there is collapse of the lateral maxillary segment, squares 3 & 4; 7 & 8 or all, if bilateral, may be blacked in instead of stippled.

3. The Striped Y does not include the division between the hard and soft palates. In the modified Striped Y squares 9 & 10 represent the hard palate and are bordered by two lines on either side (indicating hard palate) while square 11 represents the soft palate and is bordered by one line on either side.

4. In the Striped Y there is no indication if displacement of the palatal segments in complete cleft palates. In the modified Striped Y there are two arrows, one on either side of the palate. If there is displacement of the palatal segment toward the right, an X can be drawn over the arrow on the right and if displacement is toward the left, the X can be drawn over the arrow on the left.

5. The Striped Y does not give information about the state of the velopharyngeal closure. In the modified Striped Y the circle 12 represents the posterior pharyngeal wall. If there is a good velopharyngeal closure, a line is drawn along the presented dots to connect circle 12 with square 11. If there is no velopharyngeal closure no line should be drawn. Various degrees of velopharyngeal incompetence can be represented by varying the length of the line drawn.

6. The Striped Y does not record the condition of the premaxilla. In the modified Striped Y, circle 13 represents the premaxilla. If there is protrusion of the premaxilla, a line is drawn along the presented dots in the direction of the arrow. The length of that line will indicate the amount of premaxillary protrusion.

In a submucous cleft of the palate, the submucous section is cross-hatched as described in the original Striped Y.

Discussion

The modified Striped Y not only acts as a symbolic representation of the cleft lip and palate deformity in the untreated patient, but also it describes the exact condition of the patient embryologically, clinically and pathologically. Moreover, it describes the progress of the patient before, during and after treatment, by comparing the Striped Y's. This will eliminate time consuming reviewing of their large charts.

Summary

A modified Striped Y is suggested. It has the following advantages over the original Striped Y.

1. It gives information about the degree of cleft lip.
2. It indicates the presence or absence of collapse of the alveolar arch.
3. It describes the state of the hard and soft palate as a separate identity.
4. It describes the position of the palatal segments in complete cleft palate.
5. It indicates the presence or absence of velopharyngeal closure, thus giving some idea of the patient's speech.
6. It indicates the absence or presence of a protruding premaxilla and the degree of the protrusion.
7. It facilitates comparison between different patients and different stages in the same patient (preoperative and postoperative).

Acknowledgments. I wish to thank Dr. D. A. Kernahan for his very helpful suggestions and Dr. R. Millard for his encouragement in the writing of this paper.

References

1. CONWAY, H., MCKINNEY, P., CLIMO, M., HUGO, N., COLE, R., and GOULIAN, D., A Cleft Palate Registry in Action. *Plast. reconstr. Surg.*, 41, 38, 1968.
2. KERNAHAN, D. A., The Striped Y—A New Classification For Cleft Lip and Palate. *Plast. reconstr. Surg.*, 47, 469–470, 1971.
3. KERNAHAN, D. A., and STARK, R. B., A New Classification For Cleft Lip and Palate, *Plast. reconstr. Surg.*, 22, 435, 1958.