Maxillary Arch Dimensions in Bilateral Cleft Lip and Palate Subjects

A. G. HUDDART, B.D.S., F.D.S., D. ORTH., R.C.S.
Wordsley, Near Stourbridge, Worcestershire, England

In order to rationalize the treatment of cleft lip and palate conditions, it is essential to be able to effectively measure the maxillary arch so that the results of different treatment procedures may be compared.

While this is a relatively simple matter after the teeth have erupted it is highly probable that the degree of excellence of the final result will also depend to some extent on the severity of the original condition.

To enable a truly valid comparison of different treatment methods to be undertaken, therefore, it is also necessary to measure the dimensions of the maxillary arch at birth so that cases of similar type and severity may be selected for such investigations.

At the Birmingham Regional Plastic Unit, England, a method has been devised for doing this and details of this have already been published elsewhere by Huddart (*1*), and Huddart, MacCauley, and Davis (*2*).

In order to establish standards whereby the severity of individual cases should be judged, it was considered desirable however, as a preliminary measure, to obtain average values for the maxillary arch dimensions in cleft palate subjects and to compare these with those found in normal cases.

We have previously compared 30 normal and 30 unilateral cleft lip and palate subjects at birth (*2*) and the study now to be presented complements that previous work by measuring the maxillary arch dimensions of 30 newborn bilateral cases and comparing these with the 30 unilateral and 30 normal subjects already measured.

Procedure

The material for the present study was obtained from cases referred to the Birmingham Regional Plastic Unit and consisted of 30 subjects with complete bilateral clefts of the lip, alveolus and palate.

Mr. Huddart is Orthodontic Consultant to the Birmingham Regional Hospital Board.

This study was carried out under the auspices of the Research Sub-Committee of the Birmingham Regional Hospital Board.

This paper was presented at the 1969 International Congress on Cleft Palate, Houston.

The average age of the samples was 5.7 days (ranging from 0 to 14 days) and in none of the cases was there a tissue bridge of any kind present across the cleft.

Composition (Parabar) impressions were taken of the infants' upper jaws and plaster models cast from these, which were then photocopied and measured.

Photocopying and Analysis of Models

In general, the method used involved photocopying the models before and after sectioning in various planes. The same procedure was used in this study that had been used in the earlier two studies (*1, 2*). Indeed, the location of the land marks and their marking on the models was done by the same person (AGH) as in the previous investigations in order to reduce errors to a minimum. As in the previous studies, prior to being photocopied, all the models were placed face downwards and the base then made parallel with the horizontal plane which these models assumed.

THE HORIZONTAL VIEW. To facilitate identification on the horizontal photocopies, the crest of the alveolar ridge, the margins of the palatal cleft and premaxilla, post gingivale on each side, the center point of the posterior end of the nasal septum, the center point of the nasal septum where it met the premaxilla and where the line joining the anterior dental papilla to the labial frenum met the crest of the alveolar ridge on the premaxilla (prosthion) were marked. To reduce the possibility of error in the location of these points, the models were duplicated using a high accuracy duplicating material and the duplicate model similarly marked.

The original and duplicate models were each photocopied twice to reduce any error involved in locating the points which had been marked on the models on the photocopies and also to reduce any error involved in the drawing of construction lines. Finally, all measurements were taken twice to reduce experimental errors still further.

When analyzing the horizontal photocopies, a fundamental problem was the absence of a suitable transverse posterior base line (posterior palatal plane). In unilateral subjects, prosthion (called point 'A' on the photocopies) was considered to be relatively stable anteroposteriorly because the arch was intact on the one side. This enabled the posterior palatal plane to be postulated as lying 20 mm behind point 'A' and at 90° to the line of the posterior end of the underside of the nasal septum (paramidline plane). In the bilateral cases, however, direct examination of the subjects themselves revealed that in nearly all cases, there was considerable lateral divergence of the nasal septum from the midline, and the line of the underside of the septum could not therefore be used to establish anteroposterior and transverse planes. Furthermore, the position of prosthion, because it was situated on the premaxilla with a cleft on each side, could not be stable anteroposteriorly, relative to the cranium.

To overcome these difficulties, therefore, a line joining post gingivale

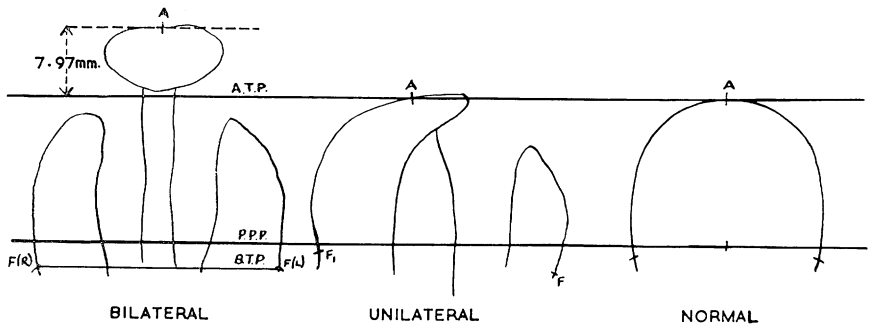

FIGURE 1. Diagram of photocopies of the maxillary arches of bilateral, unilateral and normal subjects in the horizontal view. The outlines of the crest of the alveolar ridge, the margins of the clefts and the nasal septum are shown. *A:* where a line joining the anterior dental papilla to the labial frenum crosses the crest of the alveolar ridge (prosthion on the model). *BTT:* the basic transverse plane joining post gingivale on the right side F(R) to that on the left F(L). *PPP:* the posterior palatal plane running transversely 4.32 mm anterior to the basic transverse plane in the bilateral cases and 20 mm posterior to point A (prosthion) in the unilateral and normal cases. *ATP:* the anterior transverse plane running through point A in the normal and unilateral cases together with its location on the bilateral photocopy 20 mm anterior to the posterior palatal plane (PPP). The protrusion of the premaxilla is measured by the distance from point A to the anterior transverse plane (averaging 7.97 mm in the present study).

on each side was used instead as the basic transverse plane, because it was considered that the anteroposterior position of the buccal segments would be the same on each side relative to the cranium, due to the absence of any soft tissue bridges in the cases selected (Figure 1).

It was also considered that the lesser segment in a unilateral case and the buccal segments in a bilateral subject would have comparable anteroposterior positions relative to the cranium since neither had any functional attachment to the nasal septum, the clefts in all cases being complete.

Since post gingivale on the lesser segment in unilateral cases had already been found on the average to lie 4.32 mm behind the posterior palatal plane (*2*), this enabled a second transverse plane to be drawn parallel to, and 4.32 mm anterior to, the existing one to represent the posterior palatal plane in the bilateral subjects (Figure 1). A further plane (the anterior transverse plane) was then drawn 20 mm anterior to the posterior palatal plane to represent in the bilateral cases, a plane which, in the unilateral cases, would run through point 'A' (Figure 1).

While it was not possible to obtain the true midline plane because there was no means of relating the plaster models spatially to the cranium, a paramidline plane was established by drawing a line at 90° to the posterior palatal plane which also ran through the midpoint of the extreme posterior end of the underside of the nasal septum (point G, Figure 2).

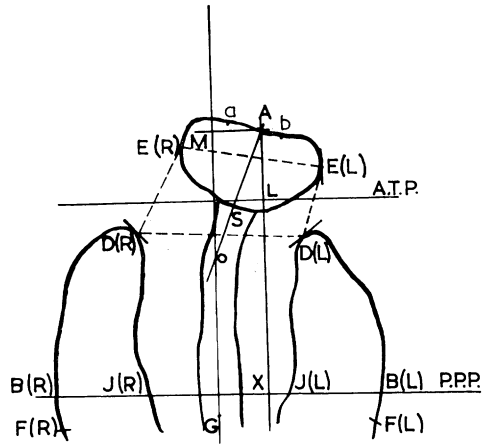

FIGURE 2. Diagram of a photocopy of a maxillary arch with a bilateral cleft of the lip, alveolus and palate in the horizontal view. The thick outlines represent the crest of the alveolar ridges and the margins of the cleft and premaxilla. The nasal septum is represented by the dotted lines. The following points are marked: *A:* prosthion (defined in Figure 1). *ATP:* the anterior transverse plane (defined in Figure 1). *PPP:* posterior palatal plane (defined in Figure 1). *B(R)* and *B(L):* where the posterior palatal plane crosses the crests of the alveolar ridges on the right and left buccal segments respectively. *D(R)* and *D(L):* where a line at 45° to the posterior palatal plane touches the anterior end of the buccal segment on the right and left sides respectively. *G:* the midpoint of the underside of the extreme posterior end of the nasal septum. The paramidline plane is drawn through *G* at 90° to the posterior palatal plane. *E(R)* and *E(L):* where a line parallel to the paramidline plane touches the lateral aspect of the premaxilla on the right and left sides respectively. *J(R)* and *J(L):* where the posterior palatal plane cuts the margin of the palatal cleft on the right and left buccal segments respectively. *F(R)* and *F(L)*: post gingivale on right and left sides respectively. *S:* where the posterior margin of the premaxilla crosses the midline of the nasal septum. *M:* where a line through A, parallel to the posterior palatal plane, cuts the paramidline plane. *L:* where a line through A, parallel to the paramidline plane, cuts the anterior transverse plane. *X:* where a line through A, parallel to the paramidline plane cuts the posterior palatal plane. *O:* where the line *AS* cuts the paramidline plane. The line aAb marks the plane along which the anterior transverse section of the model is made (Figure 4).

The following factors were measured or calculated. *aH* (overall size): the area enclosed by a line A-E(R)-D(R)-B(R)-B(L)-D(L)-E(L)-A. *bH* (area right segment): the area enclosed by a line D(R)-B(R)-J(R)-D(R). *cH* (tissue area right segment): bH / cosine angle iT (angle iT is defined in Figure 3). *dH* (area left segment): the area enclosed by a line D(L)-B(L)-J(L)-D(L). *eH* (tissue area left segment): dH / cosine angle jT (angle jT is defined in Figure 3). *fH* (area of premaxilla): the area enclosed by a line A-E(R)-S-E(L)-A. *gH* (tissue area premaxilla): fH / cosine angle AQR (angle AQR is illustrated in Figure 5). *hH* (total tissue area): cH + eH + gH. *iH* (cleft area): E(R)-D(R)-J(R)-J(L)-D(L)-E(L)-S-E(R). *jH* (lateral displacement of premaxilla): line AM. *kH* (protrusion of premaxilla): line AL. *lH* (width of premaxilla): line E(R)E(L). *mH* (width for premaxilla): line D(R)D(L). *nH* (premaxilla reposition index): mH / lH. *oH* (horizontal rotation of premaxilla): angle AOM. *pH* (right side width): line B(R)X. *qH* (left side width): line B(L)X. *rH* (ratio of asymmetry): pH (right side) / qH (left side). *sH* (ratio of asymmetry): pH (greater width) / qH (lesser width), or qH / pH as the case may be. *tH* (ratio of asymmetry:lesser width/greater width): 1 / sH.

The various markings used on the horizontal photocopies in the study are shown in Figure 2, and to simplify terminology the naming of the points is identical on both sides except that those on the right hand side have an 'R' after them and those on the left have an 'L'.

THE TRANSVERSE VIEW. After being photocopied in the horizontal plane, the duplicate models were sectioned along the posterior palatal plane to make a posterior transverse section (Figure 3) and the cut surface photocopied. Because, prior to photocopying, the base of the model had been trimmed parallel to the horizontal plane of orientation, the angles the sides of the palate made with the base could be regarded as an index of the slope of the palatal shelves (the sides of the palate).

Prior to photocopying, to assist identification, the crest of the alveolar ridge on each side and the margins of the palatal cleft were marked on the cut surface of the models. The land marks used are identified and defined in Figure 3.

In order to obtain some indication of the rotation of the premaxilla around a horizontal anteroposterior axis, the front of the duplicate model was now sectioned along the line corresponding to the crest of the alveolar ridge in the region of the future deciduous central incisors, (aAb, Figure 2) to make an anterior transverse section (Figure 4). The crest of the alveolar ridge was marked to assist identification and then the cut surface photocopied twice. The angular rotation of the premaxilla could then be assessed by measuring the angle the crest of the ridge made with the base of the model.

THE SAGITTAL VIEW. The duplicate models were finally sectioned

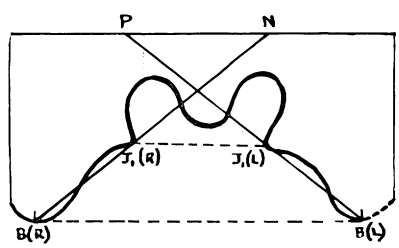

FIGURE 3. Diagram of a photocopy of a maxillary arch in the posterior transverse view. The section is made in the posterior palatal plane and the base of the model is trimmed so that it is horizontal when the model is placed face downwards on its alveolar ridges. Landmarks are the following. *B(R)*: crest of the alveolar ridge on the right side. *B(L)*: crest of the alveolar ridge on the left side. $J_1(R)$: margin of the palatal cleft on the right side. $J_1(L)$: margin of the palatal cleft on the left side. *N*: where the extension of straight line $B(R)J_1(R)$ cuts the base of the model. *P*: where the extension of the line $B(L)J_1(L)$ cuts the base of the model.

The following factors were measured or calculated. *aT* (cross section area): the area enclosed by a line $B(R)$-$J_1(R)$-$J_1(L)$-$B(L)$-$B(R)$. *bT* (posterior arch width): B(R)-B(L). *cT* (mean palatal height): aT / bT. *dT* (unit palatal height): cT / bT. *eT* (palatal cleft width): $J_1(R)$-$J_1(L)$. *fT* (right segment tissue width): straight line B(R)-$J_1(R)$. *gT* (left segment tissue width): straight line B(L)-$J_1(L)$. *hT* (total tissue width): fT + gT. *iT* (slope of right segment): angle B(R)NP. *jT* (slope of left segment): angle B(L)PN.

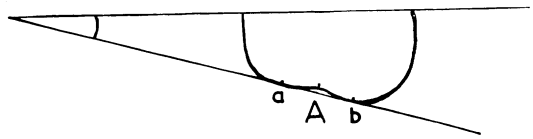

FIGURE 4. Diagram of a photocopy of an anterior transverse section through the premaxilla along the line aAb (Figure 2). The base of the model is trimmed parallel to the general horizontal plane and the rotation of the premaxilla (kT) measured by the angle an extension of the line of the crest of the alveolar ridge (ab) makes with the base.

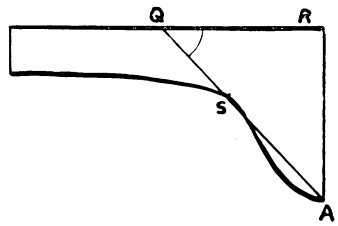

FIGURE 5. Diagram of a photocopy of a sagittal section of the premaxilla. This is a section along the line AS in Figure 2. The points A and S are marked and extended to meet the base of the model at Q. The point R represents the anterior end of the base of the model, and because the base is trimmed to represent the general horizontal plane, the slope of the premaxilla (aS) is given by the angle AQR.

along a plane corresponding to the line AS on the horizontal photocopies (Figure 2) and the palatal surface of the premaxilla and points A and S marked. The cut surface was then photocopied twice and the slope of the premaxilla measured (Figure 5).

Linear measurements were made with a Vernier caliper gauge reading to 0.1 mm and area measurements with a planimeter.

The factors studied are identified by letters as shown in the legends to Figures 2, 3, 4, and 5 and Tables 1 and 2 for easy reference.

Factors studied on the horizontal photocopies are followed by H (for example, aH, bH, cH, etc.); on the transverse by T (for example, aT, bT, cT, etc.) and on the sagittal by S (for example, aS) to facilitate their identification. This also differentiates the bilateral factors from the unilateral and normal factors studied earlier, as the latter are *prefixed* with an H or a T as the case may be (that is, aT represents overall size in the bilateral cases and Ta overall size in the normal or unilateral subjects).

Results

The results were subjected to statistical analysis and the mean values for the different factors studied are summarized in Tables 1 and 2, which also give the maximum and minimum values and the standard deviations obtained.

In Tables 3 and 4 are reprinted the values for the factors reported

TABLE 1. Results (horizontal view). The factors investigated are defined in the legend to Figure 2.

	aH	*bH*	*cH*	*dH*	*eH*	*fH*	*gH*	*hH*	*iH*	*jH*
	overall size mm²	*area right segment mm²*	*tissue area, right segment mm²*	*area left segment mm²*	*tissue area, left segment mm²*	*area of premaxilla mm²*	*tissue area, premaxilla*	*total tissue area mm²*	*cleft area mm²*	*lateral displacement of premaxilla mm*
mean	750.67	149.75	192.66	150.29	196.12	119.00	150.67	539.45	333.67	5.31
minimum	532.50	100.00	132.00	95.00	127.84	71.25	94.88	384.64	241.25	0.33
maximum	970.00	198.75	283.56	200.00	269.14	202.50	253.57	775.08	465.00	16.21
SD	98.50	24.65	34.41	26.32	34.65	30.01	36.11	84.63	60.38	3.84
	kH	*lH*	*mH*	*nH*	*oH*	*pH*	*qH*	*rH*	*sH*	*tH*
	protrusion of premaxilla mm	*width of premaxilla mm*	*width for premaxilla mm*	*premaxilla reposition index*	*horizontal rotation of premaxilla degrees*	*right side width mm*	*left side width mm*	*ratio of asymmetry right/left*	*ratio of asymmetry, greater/lesser*	*ratio of asymmetry, lesser/greater*
mean	7.97	16.68	16.94	1.03	16.74	18.06	17.96	1.64	2.41	0.597
minimum	3.38	12.68	9.62	0.64	0.50	6.68	2.79	0.21	1.01	0.079
maximum	13.59	24.56	23.12	1.59	58.38	35.31	31.44	12.66	12.66	0.995
SD	2.39	2.70	3.10	0.284	14.04	7.07	6.68	2.32	2.23	0.263

previously (*2*) when comparing the 30 unilateral and 30 normal subjects respectively within 14 days of birth.

Also included in Table 4 is the mean value for the palatal cleft width (Tn) for the unilateral subjects as measured on the transverse photocopies. Although this did not show any statistically significant difference from that originally obtained in the horizontal photocopies (Hn), it was considered that the use of the transverse photocopy measurement would enable a more strictly valid comparison to be made with the equivalent measurement in the bilateral cases (eT).

In Tables 5 and 6, the mean values for the three groups are compared and the statistical significance of the difference between the bilateral

TABLE 2. Results (transverse and sagittal views). The factors investigated are defined in the legends to Figures 3, 4, and 5.

	aT	*bT*	*cT*	*dT*	*eT*	*fT*	*gT*	*hT*	*iT*	*jT*	*kT*	*aS*
	oss sectional area	*posterior arch width*	*mean palatal height*	*unit palatal height*	*palatal cleft width*	*right segment tissue width*	*left segment tissue width*	*total tissue width*	*slope of right segment*	*slope of left segment*	*rotation of premaxilla*	*slope of premaxilla*
	mm²	*mm*	*mm*	*mm*	*mm*	*mm*	*mm*	*mm*	°	°	°	°
clefts												
mean	191.00	36.20	5.27	0.14	16.62	12.76	12.77	25.52	38.51	39.56	12.83	36.61
minimum	110.00	29.94	3.31	0.09	11.63	10.79	8.56	19.35	25.00	26.50	0	16.00
maximum	295.00	39.43	7.58	0.19	19.55	18.08	15.30	33.38	45.40	48.50	55.00	56.50
SD	35.63	2.30	0.848	0.022	2.09	1.48	1.36	2.57	4.48	4.73	13.82	8.97

TABLE 3. Unilateral and normal results (horizontal view). Maxillary arch dimensions of 30 normal and 30 unilateral cleft lip and palate cases at birth reproduced from the paper "Maxillary arch dimensions in the unilateral cleft lip and palate cases" (*2*). Detailed definitions of the factors investigated are given in that paper.

	Ha	*Hb*	*Hc*	*Hd*	*He*	*Hf*	*Hg*	*Hh*	*Hi*	*Hj*	*Hk*	*Hl*	*Hm*	*Hn*	*Ho*	*Hp*	*Hq*
	overall size	*cleft area*	*greater segment area*	*greater segment tissue area*	*lesser segment area*	*lesser segment tissue area*	*total tissue area*	*posterior arch width*	*intact side width*	*normal right side width*	*cleft side width*	*normal left side width*	*ratio of asym-metry*	*palatal cleft width*	*position of post gingivale (greater segment)*	*position of post gingivale (lesser segment)*	*retro-position of lesser segment*
	mm²	*mm²*	*mm²*	*mm²*	*mm²*	*mm²*	*mm²*	*mm*	*mm*	*mm*	*mm*	*mm*		*mm*	*mm*	*mm*	*mm*
clefts																	
minimum	468.75	160.00	173.75	215.06	73.75	97.72	360.99	28.49	8.20	—	19.00	—	0.29	10.35	−4.20	−0.70	−0.20
average	586.21	230.00	238.71	290.26	115.96	157.39	447.65	35.13	13.14	—	22.02	—	0.605	14.41	0.09	4.32	4.23
SD	49.81	47.11	33.04	40.35	22.55	30.42	46.60	3.14	2.48	—	2.14	—	0.13	1.87	2.51	3.06	2.83
maximum	612.50	371.25	315.00	382.50	173.75	229.76	537.24	41.66	19.20	—	27.80	—	0.89	17.96	6.10	12.90	13.40
normals																	
minimum	455.00	—	—	—	—	—	480.57	22.60	—	12.60	—	12.00	0.79	—	—	—	—
average	505.67	—	—	—	—	—	552.59	27.38	—	13.98	—	13.54	0.922	—	—	—	—
SD	33.42	—	—	—	—	—	40.63	2.98	—	1.55	—	1.70	0.01	—	—	—	—
maximum	588.75	—	—	—	—	—	672.10	37.15	—	18.15	—	18.80	0.99	—	—	—	—

TABLE 4. Unilateral and normal results (transverse view). Maxillary arch dimensions of 30 normal and 30 unilateral cleft lip and palate cases at birth reproduced from the paper "Maxillary arch dimensions in unilateral cleft lip and palate cases" (*2*). Detailed definitions of the factors investigated are given in that paper. Also included in this Table is the palatal cleft width (Tn) measured on the transverse photocopies (see text).

	Ta	*Tb*	*Tc*	*Td*	*Te*	*Tf*	*Tg*	*Th*	*Ti*	*Tj*	*Tk*	*Tl*	*Tm*	*Tn*
	cross sectional area	*mean palatal height*	*unit palatal height*	*greater segment tissue width*	*normal right tissue width*	*lesser segment tissue width*	*normal left tissue width*	*total tissue width (clefts)*	*total tissue width (normals)*	*greater segment slope*	*right palatal slope*	*lesser segment slope*	*left palatal slope*	*palatal cleft width*
	mm²	*mm*	*mm*	*mm*	*mm*	*mm*	*mm*	*mm*	*mm*	°	°	°	°	*mm*
clefts														
minimum	105.00	3.37	0.09	8.85	—	9.82	—	19.04	—	22.25	—	32.50	—	11.19
average	178.33	5.04	0.14	13.14	—	12.87	—	26.01	—	34.13	—	42.07	—	15.18
SD	40.54	0.94	0.03	1.86	—	1.30	—	2.959	—	5.74	—	4.95	—	1.84
maximum	260.00	6.67	0.19	16.60	—	15.62	—	31.72	—	44.87	—	51.50	—	18.11
normals														
minimum	50.00	2.10	0.08	—	12.30	—	12.40	—	25.30	—	16.00	—	14.75	—
average	94.50	3.38	0.12	—	15.13	—	15.00	—	30.13	—	23.25	—	23.65	—
SD	32.46	0.795	0.02	—	2.05	—	1.84	—	3.405	—	3.60	—	3.16	—
maximum	220.00	6.04	0.17	—	20.30	—	21.50	—	41.80	—	30.00	—	29.00	—

subjects, on the one hand, and the unilateral and normal, on the other, given.

The average birth weight of the 30 bilateral cases was 7 lbs, 2.2 ozs, which was not significantly different from either the unilateral (7 lbs, 0 oz) or the normal (6 lbs, 14 ozs) groups.

The birth weight in the bilateral cases was correlated with various factors; no significant findings were obtained. The absence of any significant correlation between the birth weight and the total tissue area (hH) was unexpected in view of the earlier finding in the unilateral cases that there was a correlation coefficient of 0.7126 ($P < 0.001$) between birth weight and total tissue area and, because of this, no attempt was made to break the bilateral sample down into birth weight ranges with regard to total tissue area (hH) or overall size (aH).

Correlations were also undertaken between the tissue area of the premaxilla (gH) and other factors. These revealed a significant correlation ($P < 0.01$) to exist between the tissue area of the premaxilla (gH) and the protrusion of the premaxilla (kH), .47, and another although barely significant ($P < 0.05$) between gH and the rotation of the premaxilla (kT), .43. Correlations between gH and oH (horizontal rotation of the premaxilla) and gH and jH (lateral displacement of the premaxilla) were not significant.

From the results, it was apparent that the posterior arch width (bT) was 8.82 mm greater than normal in the bilateral subjects and this was considered to be due to lateral segmental displacement, as suggested

TABLE 5. Comparison of bilateral and unilateral subjects. The bilateral factors are defined in the legends to Figures 2 and 3. Information related to the unilateral factors is given in the legends to Tables 3 and 4.

factors compared	*bilateral subjects*	*unilateral subjects*	*difference*	*significance* ($P<$)
overall size	aH 750.67 mm²	Ha 586.21 mm²	164.46 mm²	0.001
tissue area (buccal segment cf. lesser segment)	(cH + eH)/2 194.39 mm²	Hf 157.39 mm²	37.00 mm²	0.001
tissue area (buccal segment + premaxilla cf. greater segment)	(cH + eH)/2 + gH 345.06 mm²	Hd 290.26 mm²	54.80 mm²	0.001
total tissue area	hH 539.45 mm²	Hg 447.65 mm²	91.80 mm²	0.001
cleft area	iH 333.67 mm²	Hb 230.00 mm²	103.67 mm²	0.001
cross sectional area	aT 191.00 mm²	Ta 178.33 mm²	12.67 mm²	no
mean palatal height	cT 5.27 mm	Tb 5.04 mm	0.23 mm	no
unit palatal height	dT 0.14 mm	Tc 0.14 mm	—	no
posterior arch width	bT 36.20 mm	Hh 35.13 mm	1.07 mm	no
palatal cleft width	cT 16.62 mm	Tn 15.18 mm	1.44 mm	0.01
tissue width (buccal segment cf. lesser segment)	(fT + gT)/2 12.765 mm	Tf 12.87 mm	0.105 mm	no
total tissue width	hT 25.52 mm	Th 26.01 mm	0.49 mm	no
slope of sides of palate (buccal segment cf. lesser segment)	(iT + jT)/2 39.03°	Tl 42.07°	3.04°	0.02
slope of sides of palate (buccal segment cf. greater segment)	(iT + jT)/2 39.03°	Tj 34.13°	4.90°	0.001
ratio of asymmetry (lesser width/greater width)	tH 0.597	Hm 0.605	0.008	no
average weight	7 lbs 2.2 oz	7 lbs 0 oz	2.2 oz	no

by Subtelny (*3*). The amount of the displacement however, was not significantly greater than that found in the unilateral subjects (Table 5).

As the palatal cleft width (eT) was 16.62 mm, after allowing for this lateral segmental displacement, 7.80 mm of cleft width (that is, 16.62 less 8.82 mm) remained to be accounted for in other ways. The total tissue width (hT) in the bilateral subjects, however, was 25.53 mm compared to 30.13 mm in the normals.

When this tissue deficiency of 4.60 mm (15.27% of the mean tissue width of a normal intact palate) was added to the 8.82 mm because of the

TABLE 6. Comparison of bilateral and normal subjects. The bilateral factors are defined in the legends to Figures 2 and 3. Information relating to the normal factors is given in the legends to Tables 3 and 4.

factors compared	*bilateral subjects*	*normal subjects*	*difference*	*significance* ($P <$)
overall size	aH 750.67 mm²	Ha 505.67 mm²	245.00 mm²	0.001
total tissue area	hH 539.45 mm²	Hg 552.59 mm²	13.14 mm²	no
cross sectional area	aT 191.00 mm²	Ta 94.50 mm²	96.50 mm²	0.001
mean palatal height	cT 5.27 mm	Tb 3.38 mm	1.89 mm	0.001
unit palatal height	dT 0.14 mm	Tc 0.12 mm	0.02 mm	0.001
posterior arch width	bT 36.20 mm	Hh 27.38 mm	8.82 mm	0.001
total tissue width	hT 25.52 mm	Ti 30.13 mm	4.61 mm	0.001
slope of sides of palate	(kT + jT)/2 39.03°	(Tk + Tm)/2 23.45°	15.58°	0.001
ratio of asymmetry (lesser width/greater width)	tH 0.597	Hm 0.922	0.325	0.001
average weight	7 lbs, 2.2 oz	6 lbs, 14 oz	4.2 oz	no

segmental displacement, 3.20 mm of cleft width still remained. The remaining amount could be accounted for because the sides of the palate (iT and jT) were significantly steeper ($P < 0.001$) than normal. The contributions that segmental displacement and tissue deficiency and palatal slope make to the width of the palatal cleft are illustrated graphically in Figure 6.

From the above results it was possible to calculate that the width of the cleft in the posterior palatal plane is made up of the following factors in the following proportions (Figure 7): lateral displacement of the segments: 53.06% (51.05%); deficiency of tissue: 27.68% (27.14%); and increased palatal slope of the segments: 19.26% (21.81%).

For comparison purposes, the equivalent percentages for the unilateral subjects are given in brackets. These do not correspond exactly to those already published (*2*), as they have been recalculated using the mean value for palatal cleft width obtained from the transverse photocopies (Tn, Table 3) and are now strictly comparable to the bilateral figures.

For the purposes of the present study, the ratio of asymmetry was calculated in three different ways as detailed in the legend to Figure 2.

When compared to the normals, asymmetry in the bilaterals was found to be marked (Table 6) but there was no significant difference in the extent of the asymmetry between the bilaterals and unilaterals (Table 5).

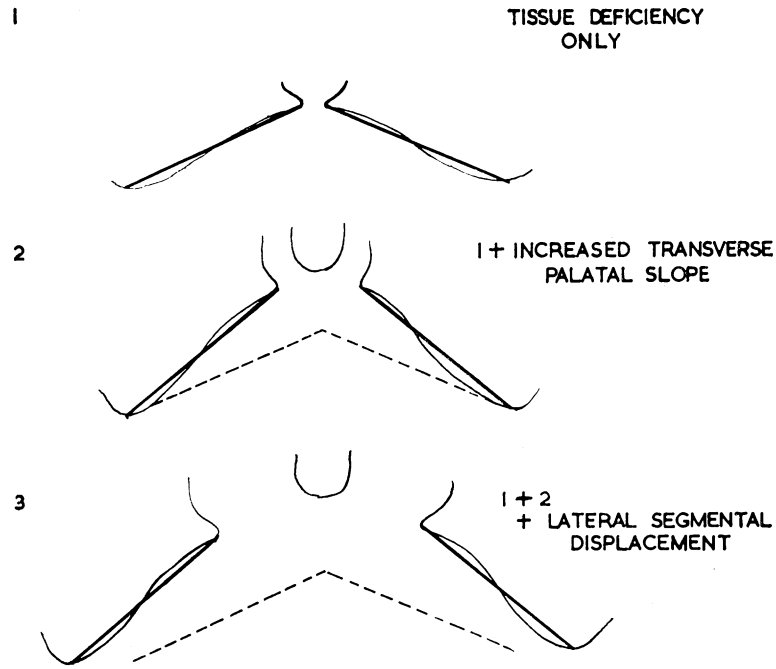

FIGURE 6. Diagrammatic representation showing how the width of the palatal cleft, as seen in transverse section, is affected by various factors. 1. Width of cleft due to a 15.27% deficiency of tissue. There is no segmental displacement and the slopes of the sides of the palate are normal. 2. Width of cleft due to a 15.27% deficiency of tissue combined with a palatal slope of 38.93° which is the average found in the bilateral subjects. There is still no segmental displacement. The dotted lines represent a normal palate. 3. Factors 1 and 2 are again shown, this time combined with the 8.82 mm lateral segmental displacement found in the bilateral subjects. These three factors combined constitute the average condition found in bilateral subjects. The dotted line represents a normal palate.

Discussion

Some of the basic differences between a bilateral cleft arch and a normal arch are shown by the superimposition of the horizontal photocopies in Figure 8.

Although the bilateral subjects had a significantly greater overall size (aH) compared with the unilateral and normal subjects due to segmental displacement (Figure 9), the most interesting finding of the investigation was the almost normal amount of tissue in the bilaterals. Since in transverse dimensions the bilaterals and unilaterals were very similar, this implies there must be a greater anteroposterior development of tissue in the bilateral cases compared with the unilaterals (Figure 10).

The comparison tests (Table 5) also revealed that the average area of tissue on a buccal segment in the bilateral subjects was significantly greater ($P < 0.001$) than on the lesser segment in the unilaterals. Fur-

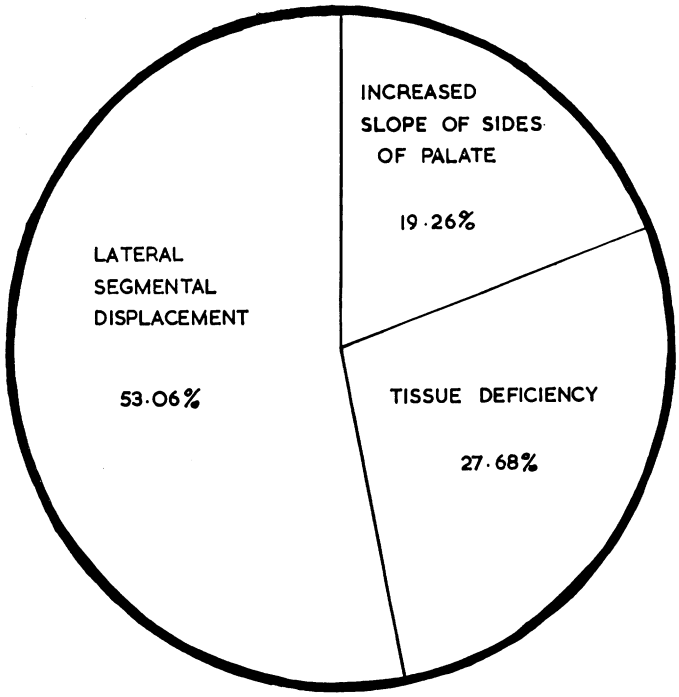

FIGURE 7. Diagram illustrating the percentage contribution made by tissue deficiency, lateral segmental displacement, and the increased slope of the sides of the palate towards the width of the palatal cleft.

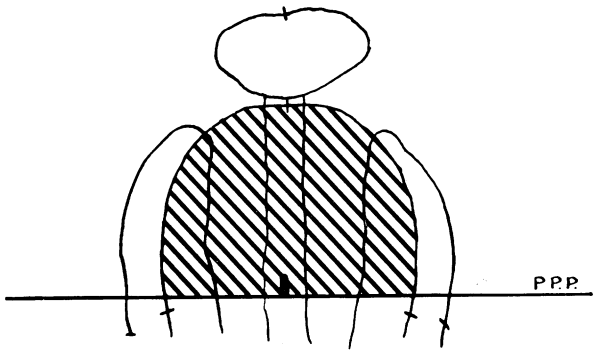

FIGURE 8. Diagram of horizontal photocopies of a bilateral cleft subject and a normal subject superimposed on the posterior palatal plane (PPP) with the posterior end of the medial palatal raphé and the center line of the underside of the nasal septum coinciding. The photocopy of the bilateral subject is unusual in that there is very little lateral displacement or rotation of the premaxilla present.

thermore, the tissue area of the premaxilla (gH) plus the average tissue area of a buccal segment was significantly higher ($P < 0.001$) than the tissue area of the greater segment in the unilateral subjects.

A possible explanation for these findings could be the opportunity for

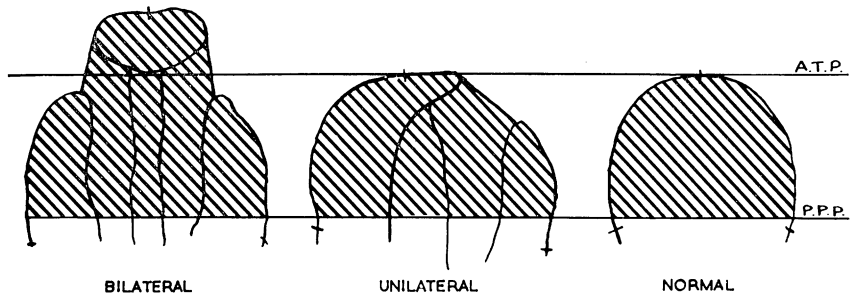

FIGURE 9. Horizontal photocopies of bilateral, unilateral and normal subjects with the overall arch size shaded. *PPP:* posterior palatal plane. *ATP:* anterior transverse plane.

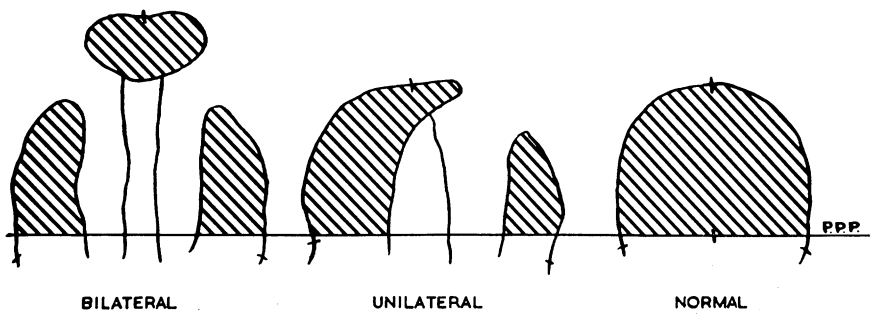

FIGURE 10. Diagram of horizontal photocopies of bilateral, unilateral and normal subjects with the area of tissue shaded to facilitate comparison. *PPP:* posterior palatal plane.

appositional growth of tissue to occur on the anterior margins of the buccal segments and the lateral margins of the premaxilla on both sides in the bilateral subjects, as opposed to on only one side in the unilaterals. This may not however be the complete explanation, and further investigations are obviously needed to clarify the situation.

Neither do these findings mean that bilateral cases present an easier surgical problem than unilaterals.

If the area of tissue (hH) is related to the cleft area (iH) and the total tissue width (hT) is related to the palatal cleft width (eT) in the bilaterals, and the ratios obtained, compared to their equivalents in the unilateral subjects, it is found that the unilateral subjects have the more favorable tissue/cleft ratios despite the greater tissue area in the bilaterals. This has already been appreciated surgically by the fact that the bilateral cleft lip with very severe premaxillary protrusion sometimes has to be closed in two stages.

The significantly greater than normal cross sectional area of the palate (aT) in the bilateral subjects (Figure 11), when related to the increased anteroposterior development already noted, means that at birth these

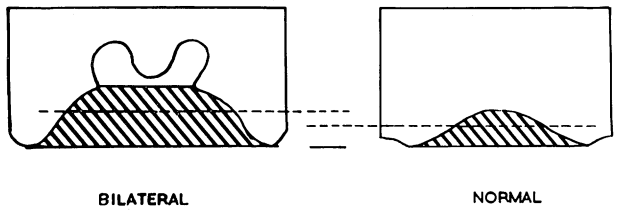

FIGURE 11. Diagram of photocopies of models of bilateral and normal subjects sectioned transversely in the posterior palatal plane. The greater cross sectional area in the bilateral cases is revealed by the shading. The mean palatal heights are shown for each case by the dotted lines. To differentiate between a narrow, high palate and a broad, shallow one, both of which could have the same mean palatal height, the unit palatal height, (that is, the average height of the palate per unit of width) may be obtained by calculating mean palatal height/posterior arch width.

children have a much greater space than normal within which the tongue has to function. Whether this gives rise to adverse patterns of tongue muscle behavior or not was impossible to say from the present study, but as it may be of importance in the development of good speech the implications of these findings should be investigated.

Although outside the scope of the present investigation, if presurgical maxillary orthopedic appliances are worn from birth onwards, these will tend to restore the cross sectional area of palate to a more normal figure and in this way possibly aid future speech development.

Regarding the transverse slope of the palate (Figure 12), this averaged 38.93° in the bilateral cases which is close to the unilateral average of 38.10° and the increased steepness in both cleft groups could be due to the tongue forcing its way into the cleft.

In the bilaterals, however, the slope was almost the same on each side, whereas in the unilaterals the slope of the lesser segment was much steeper than the slope of the greater segment.

From these findings, it would appear that in the bilateral subjects, tongue pressure is equal on both sides, whereas in the unilaterals, the

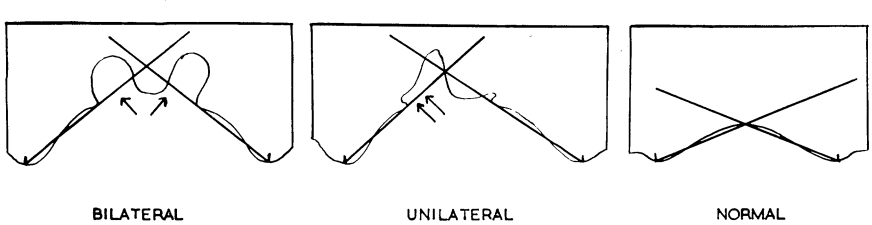

FIGURE 12. Diagram of photocopies of models of bilateral, unilateral and normal subjects sectioned transversely in the posterior palatal plane. The slope of the sides of the palate is significantly greater than normal in the cleft groups and is the same on both sides in the bilateral subjects. In the unilaterals, the slope of the lesser segment is steeper than that of the greater. The increased steepness in the cleft cases may be due to the tongue forcing its way into the cleft and the direction and extent of this pressure in the two cleft groups is suggested by the arrows.

main thrust of the tongue is on one side only because the cleft is unilateral and a disproportionate amount of the pressure is borne by the lesser segment.

One noticeable feature of the investigation was the extreme variability of the position of the premaxilla which combined lateral displacements with rotations in both vertical and horizontal planes despite the absence of any kind of soft tissue bridge whatsoever.

Correlations were therefore undertaken to see whether the position of the premaxilla could be related to either birth weight or its tissue area (gH) (Tables 7 and 8). While these tables show that birth weight has no significant influence on the position of the premaxilla, there is a significant correlation between the area of premaxillary tissue (gH) and the protrusion of the premaxilla so that the greater the area, the greater the protrusion.

Although the premaxilla on the average protruded 7.97 mm, there was probably no medial displacement of the anterior ends of the buccal segments in the cases studied, as the distance between them (mH) was 0.31 mm more than the width of the premaxilla (lH).

This was also shown by the premaxilla reposition index (nH) obtained by calculating the ratio: width for premaxilla (mH)/width of premaxilla (lH), which averaged 1.03.

Despite this, however, there is a possibility that retroposition of the buccal segments might be found to make the width between their anterior ends (mH) insufficient if their relationship to the lower arch is considered. If this were the case, it might predispose to the development of crossbites later when the dentition erupted. Because it was not possible to ascertain such intermaxillary relationships in the present study, it is suggested this ought to be investigated at some future date to obtain definite information on this point.

Although, relative to the width of the premaxilla, there is no significant medial displacement of the anterior ends of the buccal segments, there does appear to be lateral displacement of their posterior ends, because the posterior arch width was found to be significantly greater than normal ($P < 0.001$). It would appear, therefore, that the buccal segments in bilateral cases are rotated, not with their anterior ends displaced inwards, but with their posterior ends displaced outwards.

The investigations into asymmetry showed bilateral cases to be more asymmetrical than had perhaps been realized. It was also interesting to note that the ratio: right side width/left side width, labelled rH, gave a figure of 1.64, showing a tendency for the premaxilla to be displaced to the *left* (that is, making the measurement B (R) − X, (Figure 2), greater on average).

This same tendency had been found previously, although not to the same extent, in the normal cases (*2*) where the ratio: right side width/left side width was 1.031.

It would appear from these findings that there is some distorting force

operating on the maxilla, during its development or at birth, which has a greater effect on the bilateral cleft jaw because there is not the same mutual reinforcing and buttressing of the various processes present as is found in the normal subjects.

Summary

The maxillary arches of 30 newborn children with complete clefts of the lip, alveolus, and palate were measured using photocopies of plaster models of their upper jaws. The results obtained were then compared with the findings of a similar investigation involving 30 normal and 30 unilateral cleft lip and palate subjects at birth. Highly significant differences were found to exist between the bilateral subjects on the one hand and the normal and unilateral subjects on the other. In particular, the bilateral cases were found to have a significantly greater area of tissue than the unilaterals despite a transverse linear tissue deficiency of 15.27% in the posterior palatal plane. The significance of this and other findings is considered.

reprints: *A. G. Huddart, B.D.S., F.D.S., D. Orth., R.C.S.*
Birmingham Regional Plastic Unit
Wordsley Hospital
Wordsley, Near Stourbridge
Worcestershire, England

Acknowledgments: I wish to thank my colleagues, Mrs. M. E. H. Davis and Mr. F. J. MacCauley, for permission to use the material relating to normal and unilateral cases obtained from our earlier joint investigations for the purposes of the present study.

I also wish to thank my colleagues at the Birmingham Regional Plastic Unit for their advice and encouragement during the course of the investigation and Mrs. Rigby at the Royal Hospital, Wolverhampton, for undertaking all the photocopying.

I also wish to thank Mrs. M. Wall, Chief Statistician, Birmingham Regional Hospital Board and her staff, particularly Mrs. S. Kilmister, for their invaluable help with the statistical analysis and presentation of the results.

Similarly, I must acknowledge my indebtedness to Mr. Paton and his staff in the Photographic Department, Royal Hospital, Wolverhampton, for the illustrations and to Mrs. K. Randle for the typing of the paper and the preparation of the tables.

References

1. Huddart, A. G., An analysis of the maxillary changes following presurgical dental orthopedic treatment in unilateral cleft lip and palate cases. *Europ. Orthodont. Soc. Trans.*, 299–314, 1967.
2. Huddart, A. G., F. J. MacCauley, and Muriel E. H. Davis, Maxillary arch dimensions in normal and unilateral cleft palate subjects. *Cleft Palate J., 6,* 471–487, 1969.
3. Subtelny, J. D., Widths of the nasopharynx and related anatomic structures in normal and unoperated cleft palate children. *Amer. J. Orthodont., 41,* 889–909, 1955.