


# Fundamental Anatomic Findings for an Intravelar Veloplasty



OTTO B. KRIENS, DR.MED., DR.MED.DENT.

*Hamburg, West Germany*

In the normal soft palate there are two areas, which by their anatomical structures indicate the action of the muscles related to them: a) The *palatal aponeurosis* is an area of little mobility and motility (Figure 1, A). It conforms to the horizontal tendon of the tensor palati, a penate muscle, which acts mainly isometrically on the lateral edge of the Eustachian tube cartilage and pulls it down. Furthermore the palatal aponeurosis serves as attachment for a portion of the superior constrictor pharyngis muscle, i.e. the palato-pharyngeal sphincter of Whillis (12). b) Posterior to the aponeurotic portion the *muscular velum* begins without a definite boundary (Figure 1, B). Muscle fibers of isotonic action intermingle in a predominantly transverse course through the palate. Omitting the less important uvularis and glossopalatine muscles, two main bundles may be classified: the levator palati and the palato-pharyngeal muscle.

There are no fascias or gliding spaces in the normal palate, which would facilitate a clear functional or anatomical division of the muscles concerned. None of them can be dissected as a solitary individual.

## Topographic Findings

Oldfield (9) and Braithwaite (1, 3) have depicted the muscular topography of the velum in a schematic drawing, which shows the peripheral portions of the levator palati and palato-pharyngeal muscle as parts of slings within the space encircled by the superior constrictor pharyngis muscle. The cleft area, however, is omitted from their drawing. An adaptation of this schematic illustration is used to explain the muscular topography in the normal and cleft palate (Figure 2).

Cleft palate conditions can be simulated, if the common portion of the intact levator palati and palato-pharyngeal muscle sling (Figure 2, upper left) is divided in midline (Figure 2, upper right) and both sections are displaced forward to the cleft posterior nasal spine. The interwoven an-

---

Dr. Kriens is Wissenschaftlicher Assistent at the University Hospital, Kieferklinik, Hamburg, West Germany.

This paper was presented at the 1969 International Congress on Cleft Palate, Houston.

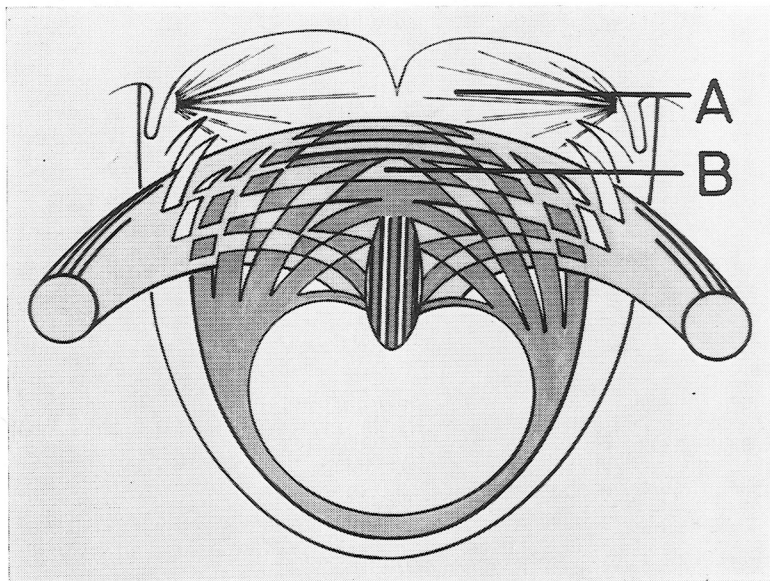


FIGURE 1. Diagrammatic illustration of the aponeurotic, A, and muscular, B, portions in the normal soft palate.

terior portions of the two muscles constitute Veau's cleft-muscle (11). In other words, the uniform cleft-muscle is not one muscle, but consists of interlacing fibers of two muscles (Figure 2, lower left) (6).

Although intermingling with the superior constrictor pharyngis muscle posterior to the entry of the levator palati into the soft palate, the cleft-muscle is distinctly separated from the superior constrictor muscle by the extension of the salpingo-pharyngeal fascia into the anterior portion of the cleft soft palate (6, 7). Under normal conditions this fascia terminates between the tensor and levator palati muscle at the membranous portion of the tube. In the cleft palate the fascia enters the velar halves anterior to the levator palati muscle and helps to form the levator space (Figure 2, lower right; Figure 3, right; and Figure 6).

### Functional Considerations

From the functional anatomic point of view the three muscular slings of the normal velo-salpingo-pharyngeal apparatus act isotonicly (Figure 4, left). Their contraction leads to the occlusion of the velopharyngeal opening. During the same action, the levator palati elevates the medial edge of the tubal cartilage. This opening movement of the Eustachian tube is furthermore afforded by the downward pull of the lateral edge of the tube by the tensor muscle and indirectly by the levator muscle, which elevates the contracting salpingo-pharyngeal muscle (Figure 6).

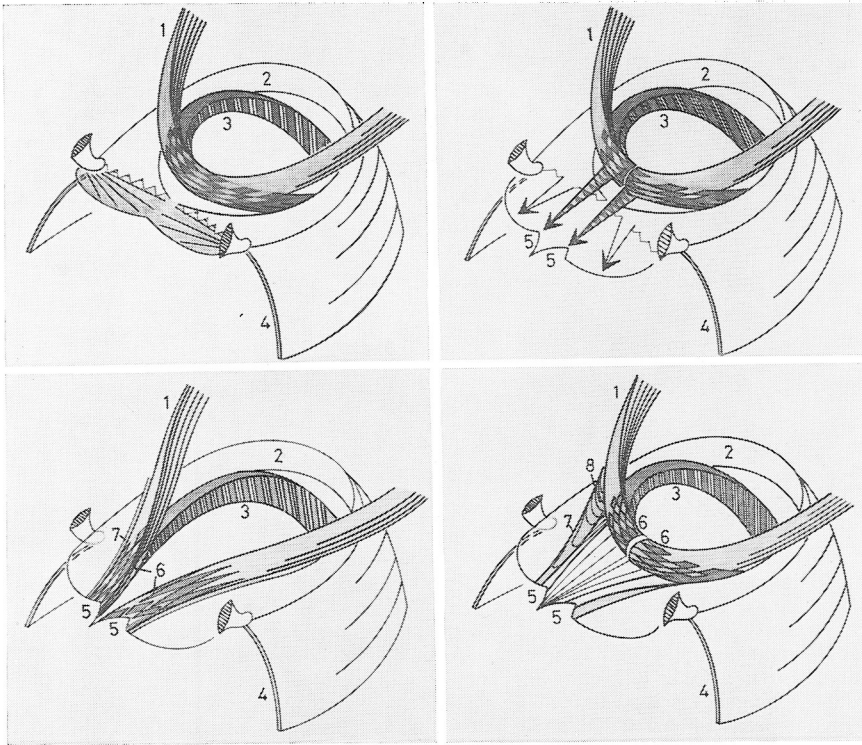


FIGURE 2. Schematic illustration of palatal muscles. *Upper left*, normal conditions of the three main muscle slings posterior to the interhamular distance and the palatal aponeurosis: levator palati muscle, 1; superior pharyngeal constrictor with palato-pharyngeal sphincter of Whillis, 2; palato-pharyngeal muscle, 3; pterygomandibular ligament with constrictor pharyngis muscle, 4. *Upper right*, the common portions of 1 and 3 are divided in midline and moved forward to the cleft posterior nasal spine, 5, to elucidate conditions in the cleft soft palate. *Lower left*, Veau's cleft-muscle, 6, is consistent with the intermingling anterior portions of the levator palati, 1, and palato-pharyngeal muscle, 3. The superior pharyngeal constrictor, 2, is separated from the cleft-muscle by the palato-salpingeal fascia, 7. *Lower right*, the major portions of Veau's cleft-muscles are joined together to form a levator sling through the repaired cleft palate. The palato-salpingeal fascia, 7, and the levator space, 8, are exposed to view.

The functional synergism of the velo-salpingo-pharyngeal muscles is impaired in the cleft palate (Figure 4; and Figure 5, top left and right). This is not only true for the action around the velopharyngeal opening, but also around the epipharyngeal portion of the Eustachian tube. With the exception of the superior pharyngeal constrictor the other muscles of the cleft palate have ipsilateral origins and insertions. The levator palati, the most important cleft palate muscle, extends in a shallow bow of paradoxical course between its two attachment areas at the same side of the head. The muscle moves laterally, forward and upward, instead of backward and upward (Figure 4; and Figure 5, top left and

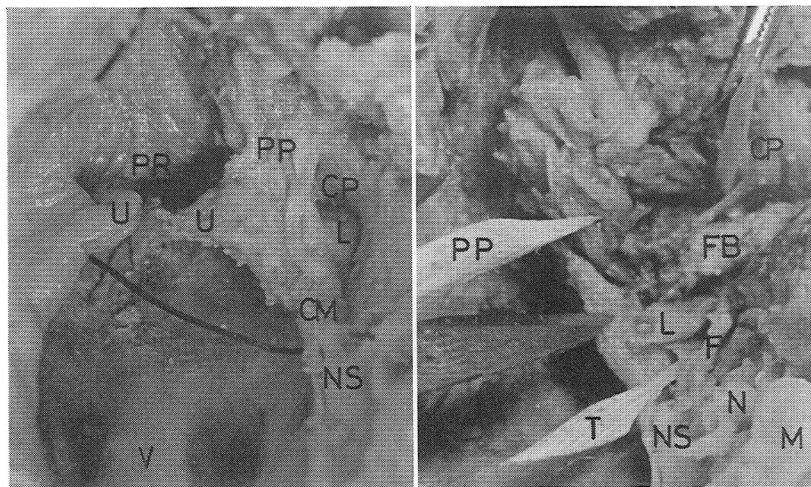


FIGURE 3. Anatomical dissection of a cleft palate (right velum). *Left*, a superficial plane. The cleft-muscle is separated from the superior pharyngeal constrictor and the levator palati exposed to view in the levator space. Black silk thread in right Eustachian tube. *Right*, a deep plane of dissection: apparent relations of the levator palati muscle (cut), L, to Eustachian tube (wooden pointer T), torus tubalis (tip of scalpel), palato-pharyngeal muscle (dissected and turned backward, wooden marker PP), palato-salpingeal fascia, F, and to fat body, FB. *Abbreviations*: CM, cleft-muscle (Vcau); CP, constrictor pharyngis muscle; F, palato-salpingeal fascia; FB, fat body; L, levator palati muscle; M, maxillary tuber; N, neurovascular bundle; NS, cleft posterior nasal spine; PP, palato-pharyngeal muscle; PR, Passavant's ridge; SP, salpingo-pharyngeal muscle; U, uvula; V, vomer.

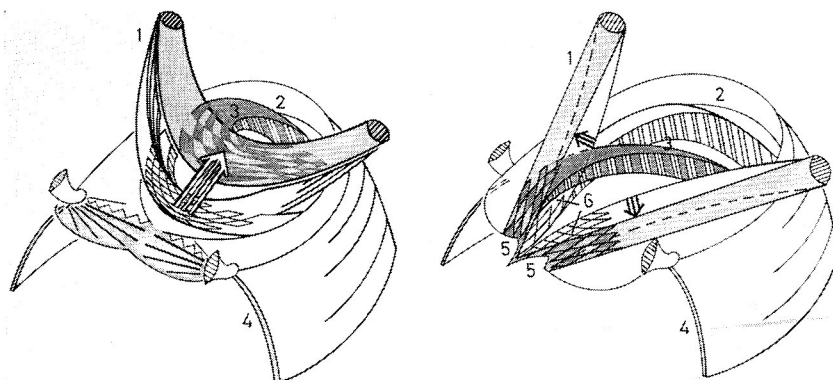


FIGURE 4. Schematic illustration of the levator palati and palato-pharyngeal muscle of the normal, *left*, and the cleft soft palate, *right*, in repose and contraction. *Left*, the two normal muscles move upward and backward on contraction (isotonic action). *Right*, in the cleft palate, the contraction of the levator palati terminates in an isometric action between its ipsilateral attachments. Paradoxical excursion indicated by arrows. Only the pharyngeal portion of the palato-pharyngeal muscle causes a narrowing of the epipharyngeal diameter (identification marks are like those in Figure 2).

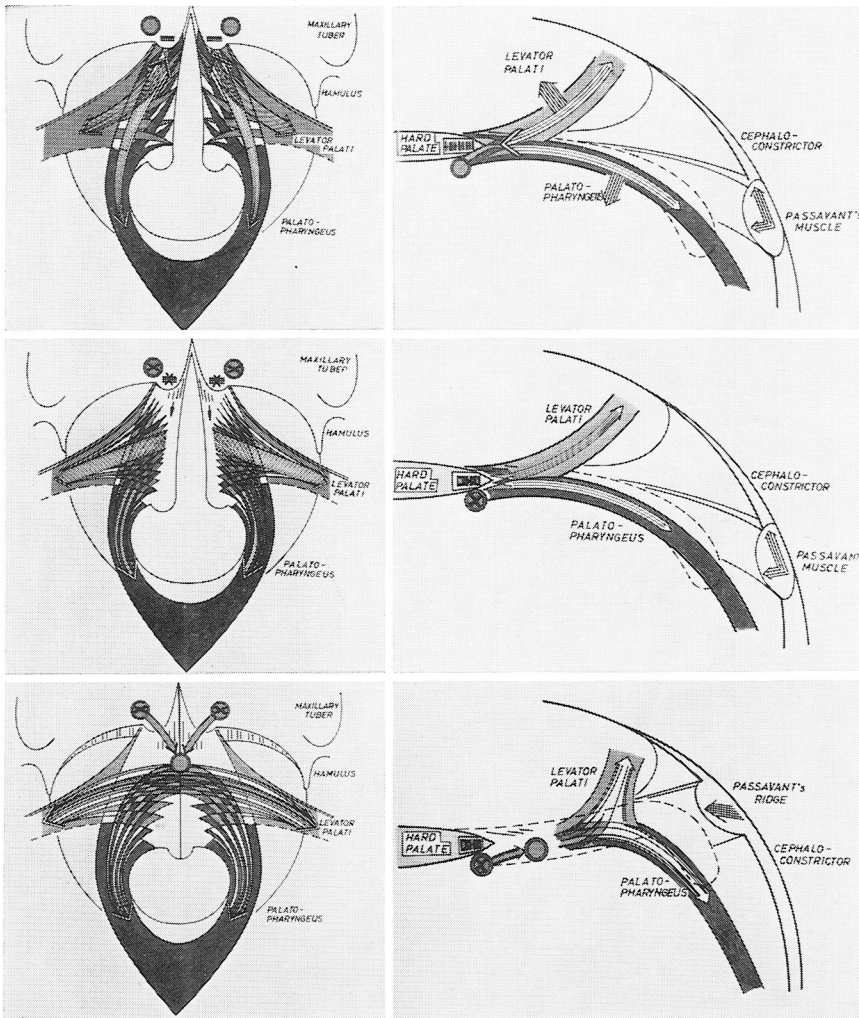


FIGURE 5. Diagrammatic drawings of the muscular topography in the cleft palate, *top*, and at two stages of the intravelar veloplasty, *middle* and *bottom*. A transversal view is accompanied by a sagittal aspect. The arrows point to the direction of the attachment and movement of the muscles. *Top*, conditions in the cleft soft palate (circle lateral of the cleft posterior nasal spine, cleft-muscle attachment at oral mucoperiosteum; horizontal lines, insertions of cleft-muscle at cleft posterior nasal spine). *Middle*, the paradoxical excursion of the cleft levator palati muscle ends with detaching these cleft-muscle insertions. *Bottom*, formation of a levator sling with retro-displacement and end-to-end union of the cleft-muscles, excepting the insertions at the nasal lining.

right). Its isotonic action soon ends in an isometric contraction, when the muscle is almost straightened between its ipsilateral attachments. The palatal halves are pulled to the sides and not posteriorly (Figure 4, right; and Figure 5, top left and right).

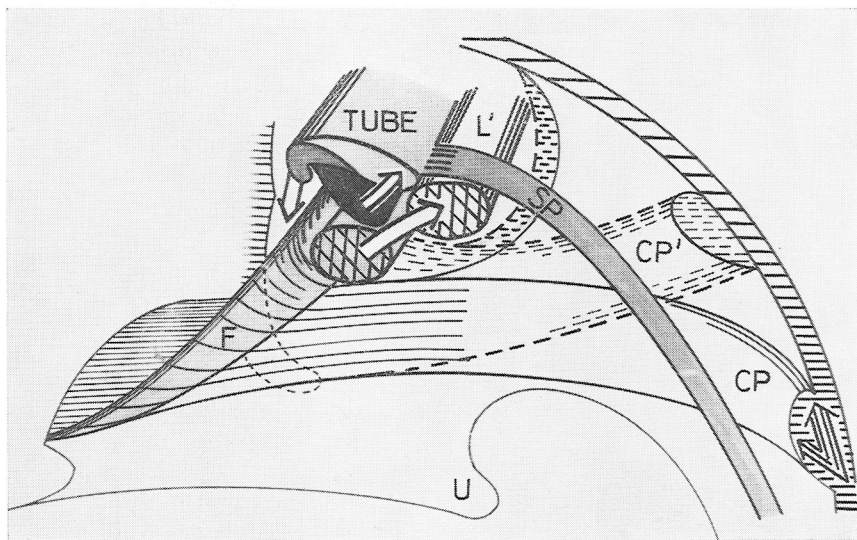


FIGURE 6. Illustration of the interplay of muscles adjacent to Eustachian tube. Only after the formation of a levator palati sling ( $L'$ ), through the repaired velum can the muscle move backward and elevate the medial edge of the tubal cartilage and the contracting salpingo-pharyngeal muscle (SP), while the tensor pulls the lateral one down. At the same time the superior pharyngeal constrictor (CP) glides cranially (to  $CP'$ ), considerably obliterating the epipharyngeal opening and the levator space (posterior to the palato-salpingeal fascia (F)).

A similar dysfunction is present in the lateral epipharyngeal wall around the levator palati muscle. Since the muscle does not meet its contralateral namesake it cannot move dorso-cranially, but deviates cranio-laterally. Therefore the medial edge of the Eustachian tube is neither directly elevated by the levator palati muscle, nor indirectly by it, elevating the contracting salpingo-pharyngeal muscle (Figure 6). Under normal conditions in the lateral epipharyngeal wall the levator palati muscle moves backward and upward during action, and with it the superior constrictor glides cranially. In the cleft palate the levator space is retained during contraction of the muscles as long as the cleft-muscle is adherent to its attachments (Figure 4, right; and Figure 5, top left and right). The detachment from its insertion at the oral mucoperiosteum and from the cleft posterior nasal spine and the formation of a muscle sling through the soft palate are prerequisites for an improvement of an effective interplay of the palatal muscles around the levator space.

### **Remarks about Surgical Procedure**

Although only the most forward portion of the cleft-muscle is operated on in the velum, the motility and course of the muscle are changed so as to improve middle ear function. From this point of view, any intervention near the epipharyngeal portion of the Eustachian tube seems to be



inappropriate and even harmful, although the closure of the cleft may be performed with greater technical ease and safety. The fracture of the hamulus may easily lead to a disruption of the musculo-tendinous apparatus near the tube. Worst of all—as far as the subsequent damage is concerned—seems packing the space of Ernst (5): immediate disturbance of the equilibrium of the muscle interrelations around the levator space, and late functional impairments, due to scar formation on the external aspect of the epipharyngeal wall and in the parapharyngeal tissues, have to be feared.

Mobilization of the velar halves in extravelar areas is unnecessary because it can be achieved by operating in the described anatomic plane within the cleft soft palate.

A palatal aponeurosis does not exist in the cleft palate. Instead, the rudimentary tensor tendon fans out to the oral tissues (Figure 8, top right) and between the superior constrictor and the cleft-muscle. Severance of these tendinous fibers allows the mobilization of the velar halves in a preformed space towards the midline (Figure 8, middle left). However, the attachments of Veau's cleft-muscle, especially its portion to the oral mucoperiosteum and to the posterior nasal spine (Figure 8, middle right and bottom left), retain the lateral position of the velar stumps and have to be freed.

Since the tensor (veli palati) muscle is fixed to the buccopharyngeal muscles by its vertical aponeurosis (Figure 7) anterior to the pterygo-mandibular ligament, the rudimentary horizontal tendon may be cut.

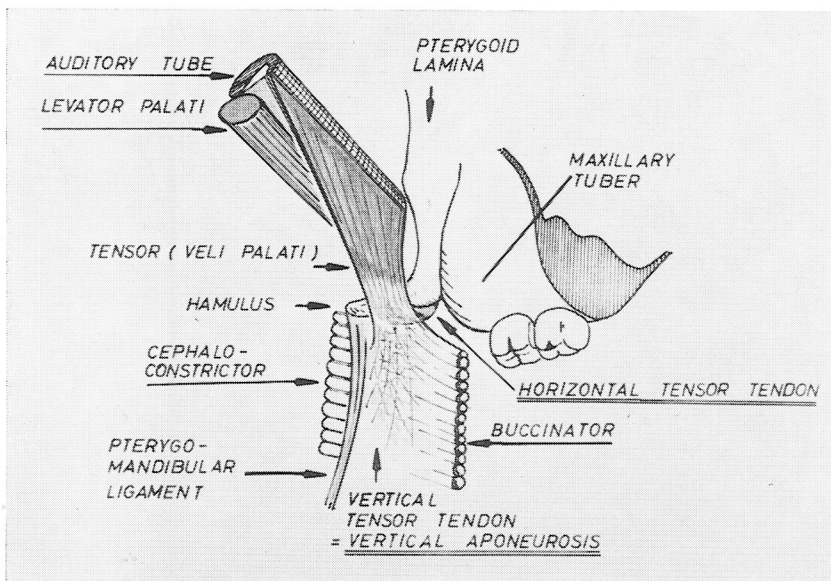


FIGURE 7. Schematic drawing of the tensor veli palati muscle inserting at the vertical and horizontal (palatine) tendon.

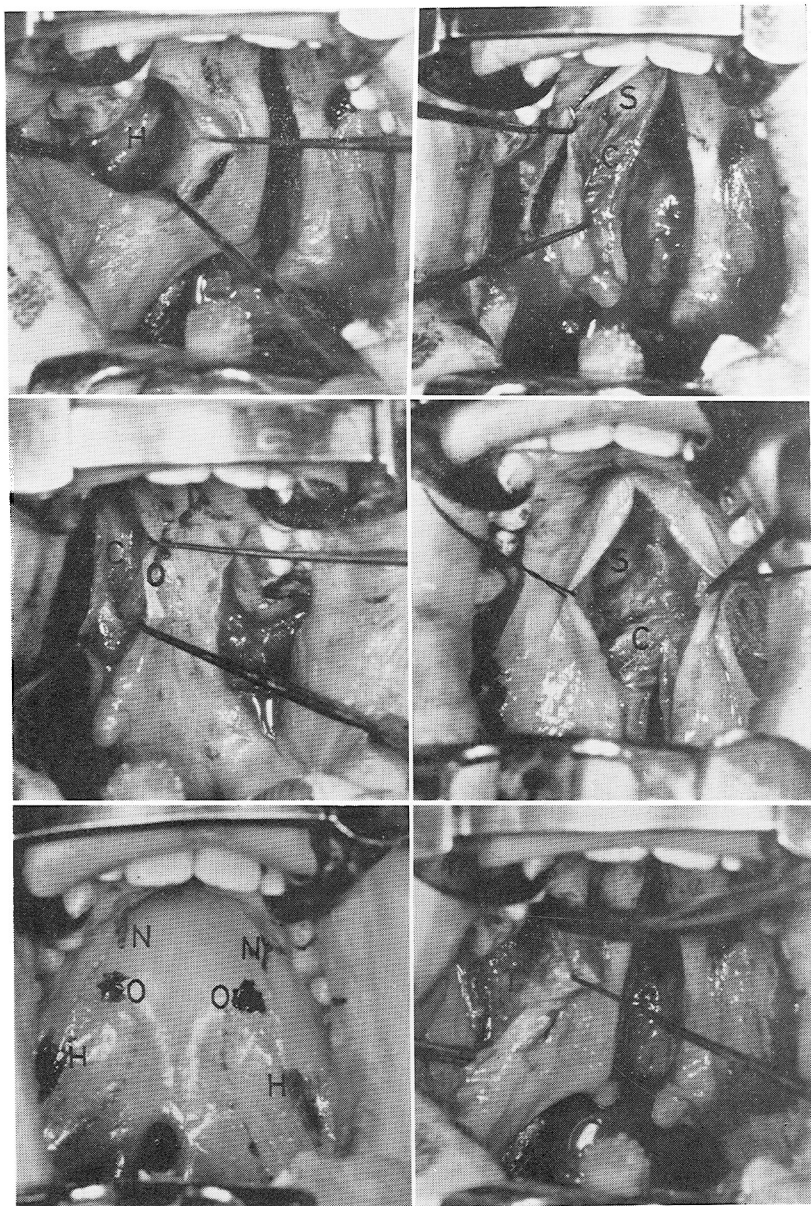


FIGURE 8. Operative photographs. *Upper left*, submucous cleft palate with ink marks at the neurovascular bundles (N), the attachment of the cleft-muscle at the oral mucoperiosteum (O), and over the hamuli (H). *Upper right*, dissection of the rudimentary tensor tendon (T) through a Dieffenbach incision. Note that some of the tendinous fibers insert at the oral lining, while others spread out into deeper layers of the soft palate. *Middle left*, gliding space between the cleft-muscle and the superior pharyngeal constrictor. It is open for blunt dissection after the horizontal tensor tendon has been severed. Note that sufficient mobilization of the velar half is achieved without further interfering with the musculo-tendinous apparatus at and lateral of the hamulus (H). *Middle right*, cleft-muscle fibers (C) inserting at posterior nasal spine (S). *Bottom left*, oral portion of cleft-muscle dissected. Note its course to the ink mark (O), which is partly hidden behind the anterior hook. *Bottom right*, formation of a levator palati sling. Observe the altered direction of the cleft-muscle fibers (C) in a considerable distance posterior to the posterior nasal spine (S). (Compare *middle right* with *bottom right*.)



In the cleft palate, the action of the tensor muscle on the lateral edge of the Eustachian tube is maintained by the strong vertical tendinous insertion.

The ultimate goal of the intravelar veloplasty is the end-to-end union of the anterior portions of the cleft-muscle in midline (Figure 2, lower right; Figure 5, bottom left and right; and Figure 8, lower right). The direct insertion of the cleft-muscle fibers at the tunica propria below the nasal epithelium should warn the surgeon against any attempt to cut close to it. Interventions other than elevating the nasal mucoperiosteum and dissecting the fibers attached to the bone, that is, operating in the hard palate area of the nasal lining, should be refrained from. If an immediate elongation of the nasal layer is necessary, a retrodisplacement after Stark's (10) or Cronin's procedure (4), or with Millard's island flap (8), should be resorted to, instead of severing the muscle attachments at the nasal lining. The latter intervention involves a great risk of a break-down of the nasal lining with subsequent scars or a fistula.

After the cleft-muscle of each side has been shifted dorso-medially and a levator sling has been formed (Figure 8, lower right), the closure of the cleft palate should be technically simple, except for a suture placed through the former attachment area of the oral mucoperiosteum. This suture provides additional security for an uneventful healing anterior to the constructed muscle sling.

The lateral incisions are closed by means of buccal mucous membrane flaps in order to prevent secondary healing.

### Summary

The topography of the cleft palate muscles is demonstrated by means of schematic and anatomic illustrations, and compared with conditions in the normal palate. Pathologic findings of the muscles are observed in the cleft velum itself. The functional aspects of the paradoxical excursion of the cleft levator palati and the muscular interaction in the lateral epipharyngeal wall are emphasized. It is concluded that the intravelar repair would offer the best chances for establishing closure of the soft palate to near normal conditions.

reprints: Dr. Otto B. Kriens  
Wissenschaftlicher Assistent  
University Hospital, Kieferklinik  
Martinistrasse 52  
Hamburg, West Germany

### References

1. BRAITHWAITE, F., Cleft lip and palate. *Clinical Surgery*, C. Rob and R. Smith (eds.), 174-189. London: Butterworth & Co., 1966.
2. BRAITHWAITE, F., and D. G. MAURICE, The importance of the levator palati muscle in cleft palate closure. *Brit. J. plastic Surg.*, 21, 60-62, 1968.
3. BRAITHWAITE, F., and M. E. MORLEY, Cleft lip and palate. *Speech Path. Ther.*, 6, 3-14, 1963.

4. CRONIN, T. D., Method of preventing raw area on nasal surface of soft palate in push-back surgery. *Plastic reconstr. Surg.*, 20, 474-484, 1957.
5. ERNST, F., Zur Frage der Gaumenplastick. *Zentralbl. Chir.*, 52, 464-470, 1925.
6. KRIENS, O., Anatomische Untersuchungen am gespaltenen weichen Gaumen. *Chir. plastica reconstr.*, 4, 14-32, 1967.
7. KRIENS, O., An anatomical approach to veloplasty. *Plastic reconstr. Surg.*, 43, 29-41, 1969.
8. MILLARD, R. D., The island flap in cleft palate surgery. *Surg. Gyn. Obst.*, 116, 297-300, 1963.
9. OLDFIELD, M., Cleft palate and mechanism of speech. *Brit. J. Surg.*, 29, 197-227, 1941.
10. STARK, D. B., Nasal lining in partial cleft palate repair. *Plastic reconstr. Surg.*, 32, 75-81, 1963.
11. VEAU, V., *Division Palatine*. Paris: Masson & Cie, 1931.
12. WHILLIS, J., A note on the muscles of the palate and the superior constrictor. *J. Anat. Phys.*, 65, 92-95, 1930.