Special Problems in Full Rehabilitation of the Nasal Base and Upper Lip in Single and Double Clefts

PROF. DR. MED. OTTO NEUNER
Bern, Switzerland

To alleviate the "hare-lip" stigma frequently associated with cleft lip following initial repair, it is necessary to remove the tell-tale signs that so dramatically stereotype the cleft-lip patient; that is the flattened, depressed nose and the lack of normal upper lip contour and profile. To accomplish this goal, it is usually necessary to perform corrective surgery not only on the lip and nasal base, but on the nose as well. In this presentation, some of the more characteristic problems will be cited and our methods for treatment given. Rhinoplastic surgical repair, while many times inseparable from complete rehabilitation, will not be discussed to its full extent; but rather, only those problems directly associated with the upper lip, nasal base, and columella will be emphasized.

In the single cleft, the defect results in the shifting of the affected ala and nasal tip toward the normal side. The surgical task, then, is to raise the collapsed nasal wing and straighten the tip, while also revising the lip. The vermilion in this case tends to be drawn upward toward the nasal base and lengthening of the philtrum area is indicated. Correction of the deviated tip and nasal base asymmetry is accomplished through surgical repair of the nasal cartilage. This can usually be done at the same time as the lip is re-operated (*6*). Slight to moderate displacement of the ala on the affected side is corrected using a VY-plasty after the method of Brown and McDowell (*1*). The affected cartilage is modified to receive support from the contralateral nasal cartilage or from a small cartilage implant (*6, 7*) (Figure 1, A–F). In severe asymmetry, the medial crus must be completely mobilized and fixed in an anterior position to the contralateral medial crural cartilage after a small triangle of skin is excised from the region of the soft triangle (Figure 2, A–F) (*6, 7*). In all degrees of displacement, it is necessary to raise a flap from the lip toward the nasal base in a fashion similar to that advocated by Millard (*3*). The flap, containing old scar, is rotated 90 degrees and sutured to the

Prof. Dr. Neuner is Professor and Chairman, Department of Maxillofacial Surgery, The University of Bern.

This paper was presented at the 1969 International Congress on Cleft Palate, Houston.

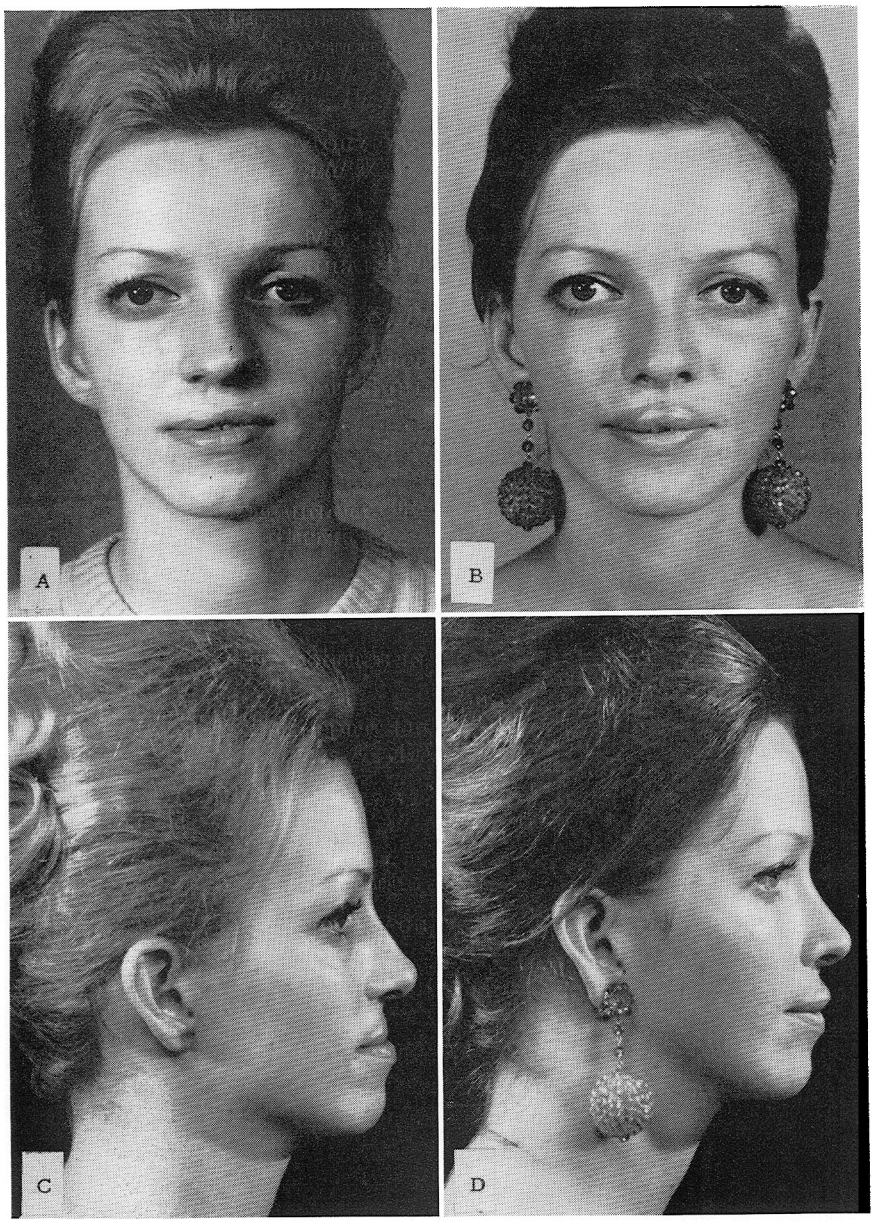

FIGURE 1. Pre- and postoperative photographs, a complete unilateral cleft.

alar base. This will both increase the vertical of the upper lip and approach restoration of the affected ala (*5*).

In double clefts, the nasal tip is depressed posteriorly and collapsed downwards. Here one must elevate the tip to restore normal form. Technically, this means that the nasal passages must be elongated. It is

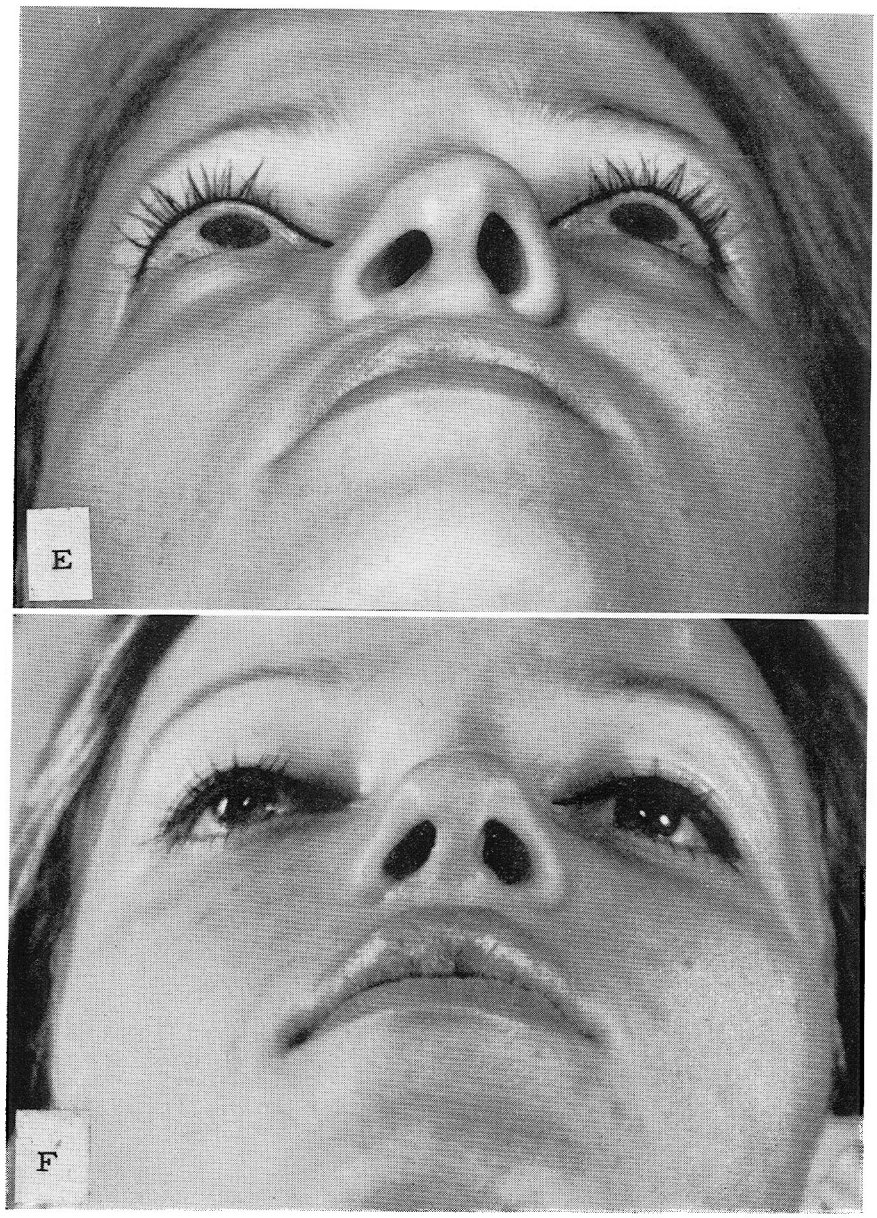

Figure 1. Continued.

possible to lengthen the passages up to 9 mm by displacing the vestibular mucosa only. Tissue along the nasolabial junction is undermined and a minor revision of the nasal vestibulum performed. With the tip elevated in this new position, the incisions are closed and the medial crural cartilage fixed (*6, 7*). It may be necessary to modify slightly this

cartilage (Figure 3, A–F). If more lengthening is required, incisions must be made in the upper lip and these sliding flaps raised with the tip in a manner after Millard (*4*). Our method differs from Millard's in that we elevate and form the alar cartilage and tip at the same time we lengthen the columella. This method has been described by Neuner (*6, 7*). The net result of these procedures helps to give a more pleasing form to the nose (Figure 4, A–F). To improve contour of the lip, the same procedure as with single clefts is employed bilaterally, that is, the raising of two forked flaps rotated 90 degrees laterally. All lip operations should be

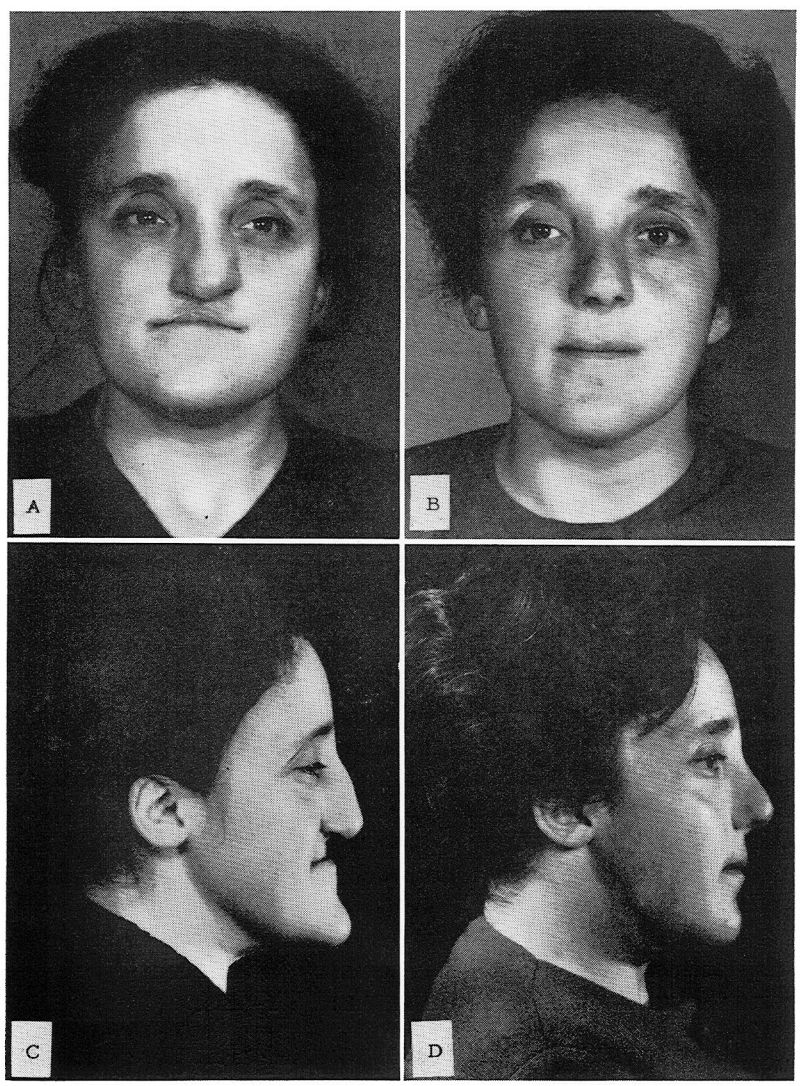

FIGURE 2. Pre- and postoperative photographs, a severe complete unilateral cleft.

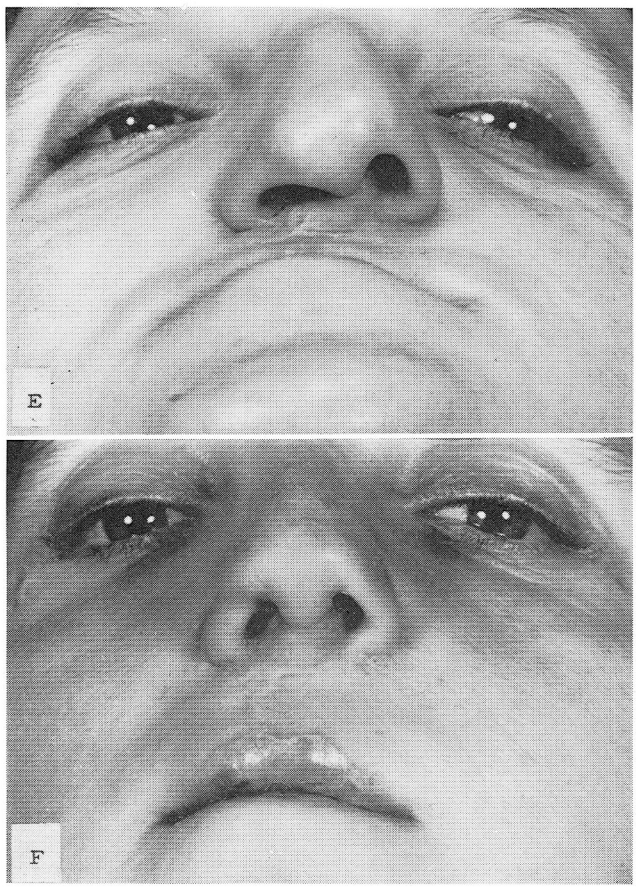

Figure 2. Continued.

planned to leave only vertical scars which more nearly correspond with the edges of the philtrum. Normal lip function in terms of whistling, pursing of the lips, and laughing, all in a functionally and visually acceptable manner, is our criterion for success.

Particular importance is also given to developing the contour of the philtrum and vermilion border (*2, 10*). In lips completely devoid of a prominent philtrum and Cupid's bow, one can construct a more esthetic lip contour by folding a small muscular flap raised from the midline of the philtrum area onto itself. This 180 degree folding produces a prominence at the labiovermilion border and a sulcus in the area from which the flap was raised. Sometimes it is necessary to shift some lip mucosa to increase the vermilion height with bilateral VY-plasty (Figure 5, A and B) (*10*).

In patients with poor lip musculature, the philtrum can be constructed using a piece of cartilage from the upper antihelix of the ear. Cartilage

from this area presents an ideally formed implant which can be inserted into the upper lip through a small vertical vermilion incision (Figure 6, A, B, and C). Schmid (*10*) demonstrated a method for building a philtrum using composite graft from the concha of the ear.

In the absence of sufficient lip mucosa, a double Z-plasty is added on the inner side of the upper lip (*5, 8*). To do so, mucosal flaps are developed medially and are shifted accordingly. The mucosa is mobilized and sutured in the midline (Figure 7, A and B).

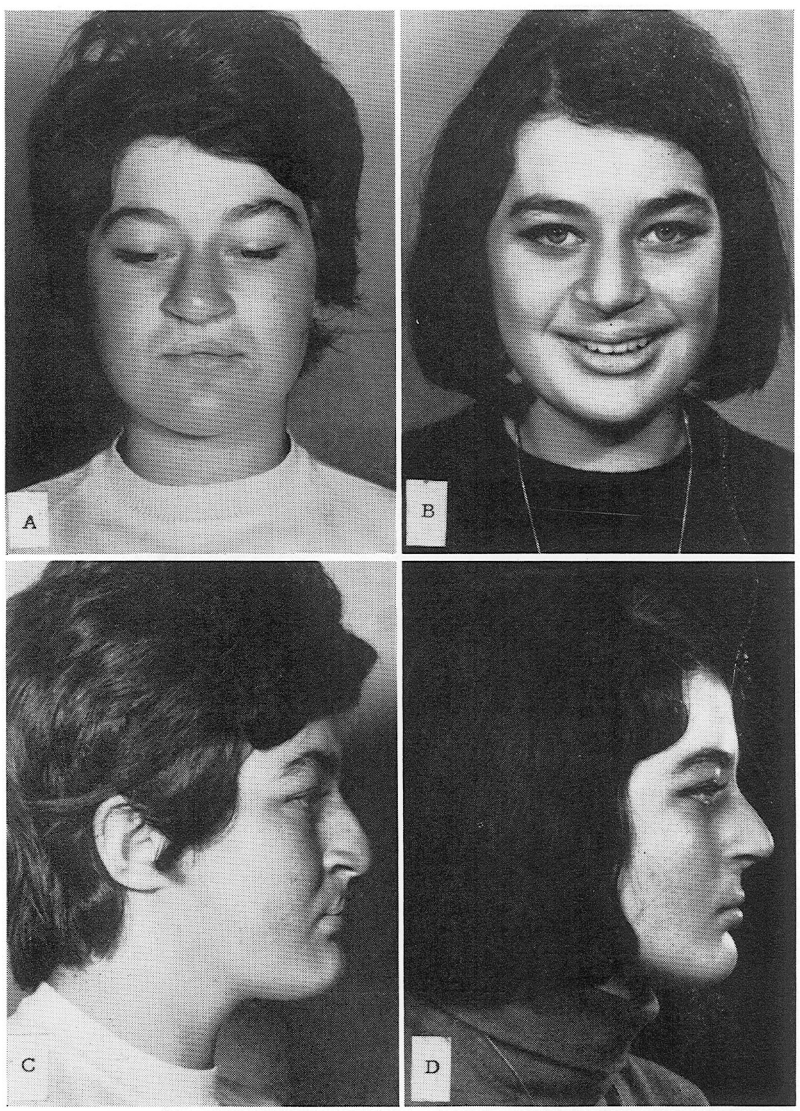

FIGURE 3. Pre- and postoperative photographs, a bilateral cleft.

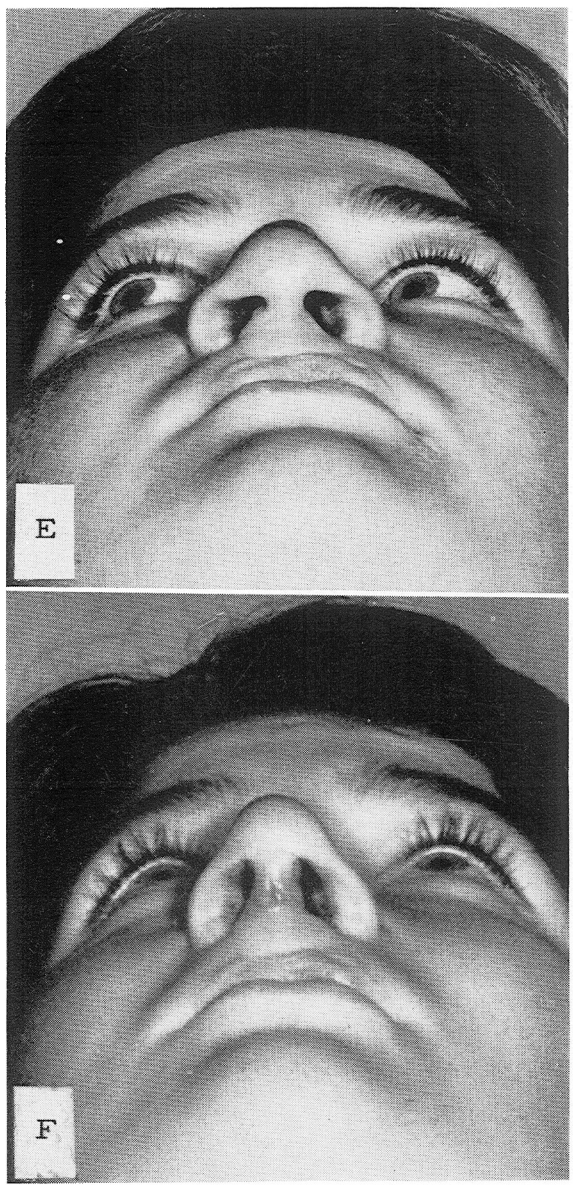

Figure 3. Continued.

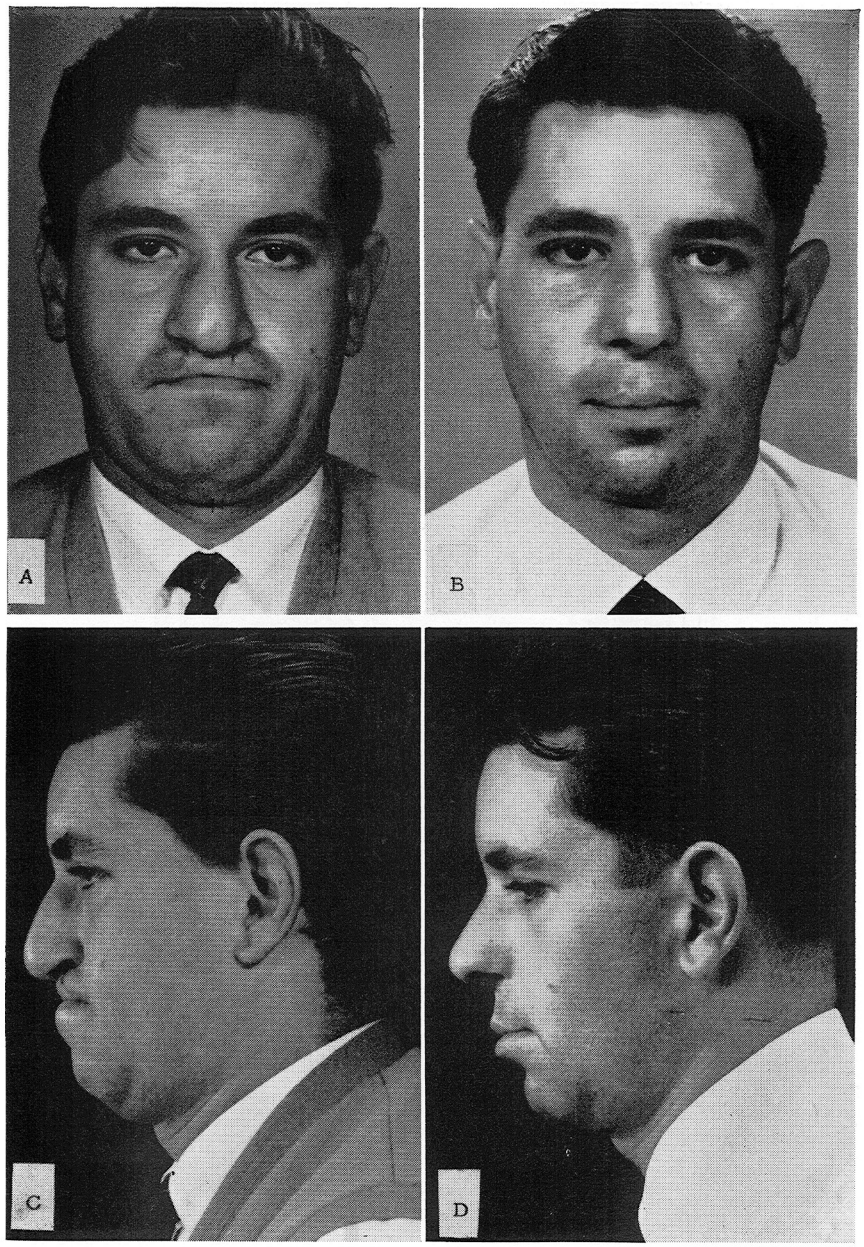

FIGURE 4. Pre- and postoperative photographs, a severe bilateral cleft.

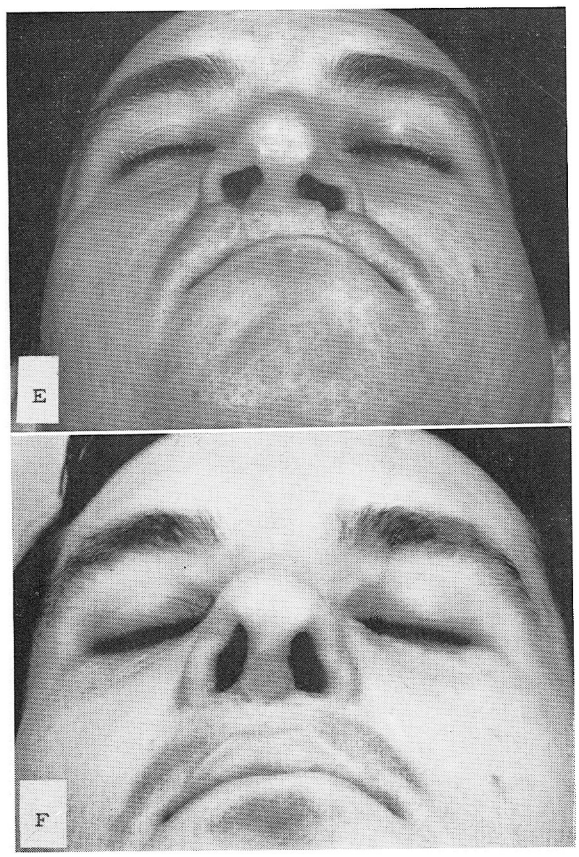

Figure 4. Continued.

If the discrepancy of volume between the atrophic upper lip and normal lower lip is exaggerated, it is necessary either to reduce the lower lip volume by an adequate excision or to transpose a visor-flap from the lower lip into the upper lip (*8*). Such a flap is based bilaterally at the commissure and the whole procedure is performed in one stage (Figure 8, A–C). Results have been so satisfactory that for the last few years we have abandoned the Abbe flap techniques.

When one considers reconstruction of the organs of mastication, of essential concern is the bony fixation on the parts of the cleft relative to one another (*9*). We accomplish this by taking a portion of bone from the inferior border on the chin and using it as an implant in the maxilla between the cleft (Figure 9, A–D). This serves to build up the atrophied alveolar arch that is anteriorly edentulous and provides stability for subsequent surgical or orthodontic procedures. Furthermore, it anticipates any future need for the alveolar arch to support a prosthesis.

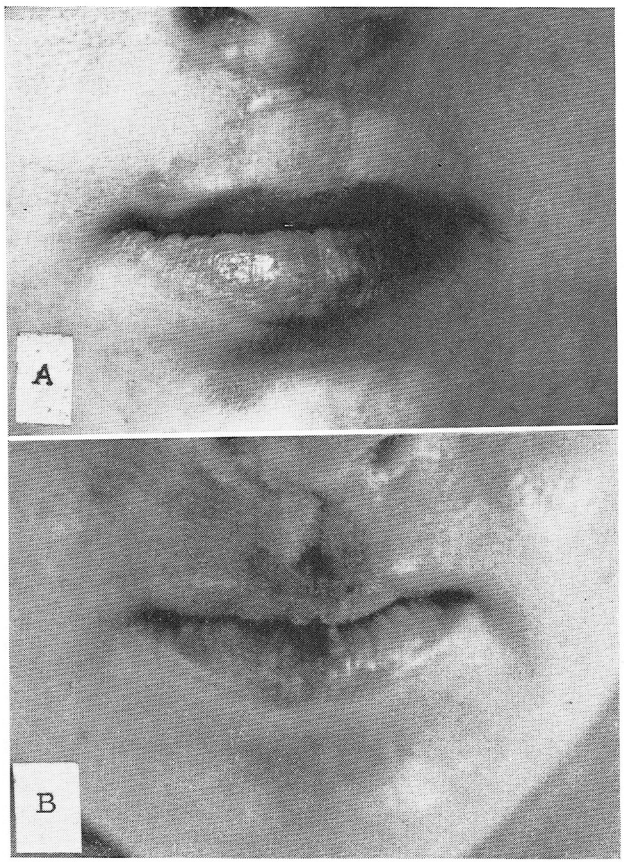

FIGURE 5. Philtrum construction using muscle flaps.

While all of the aforementioned surgical techniques have been discussed together, certainly it is not always possible to accomplish everything at the same time. Indeed, several successive operations are usually necessary to arrive at a predetermined goal. In fact, optimal rehabilitation of the cleft patient entails systematic, often slow, sectional improvement of each defect, demanding attention to minute detail, and requiring the maximal efforts of the surgeon, prosthodontist, and speech therapist.

Summary

Different methods are considered in the secondary surgical reconstruction of the upper lip-nasal base-columella complex, utilizing sliding and rotational flaps from the upper lip, and autotransplantation of ear and nasal cartilage and chin bone. Likewise, special attention is given to the construction of the philtrum. Different methods are discussed for phil-

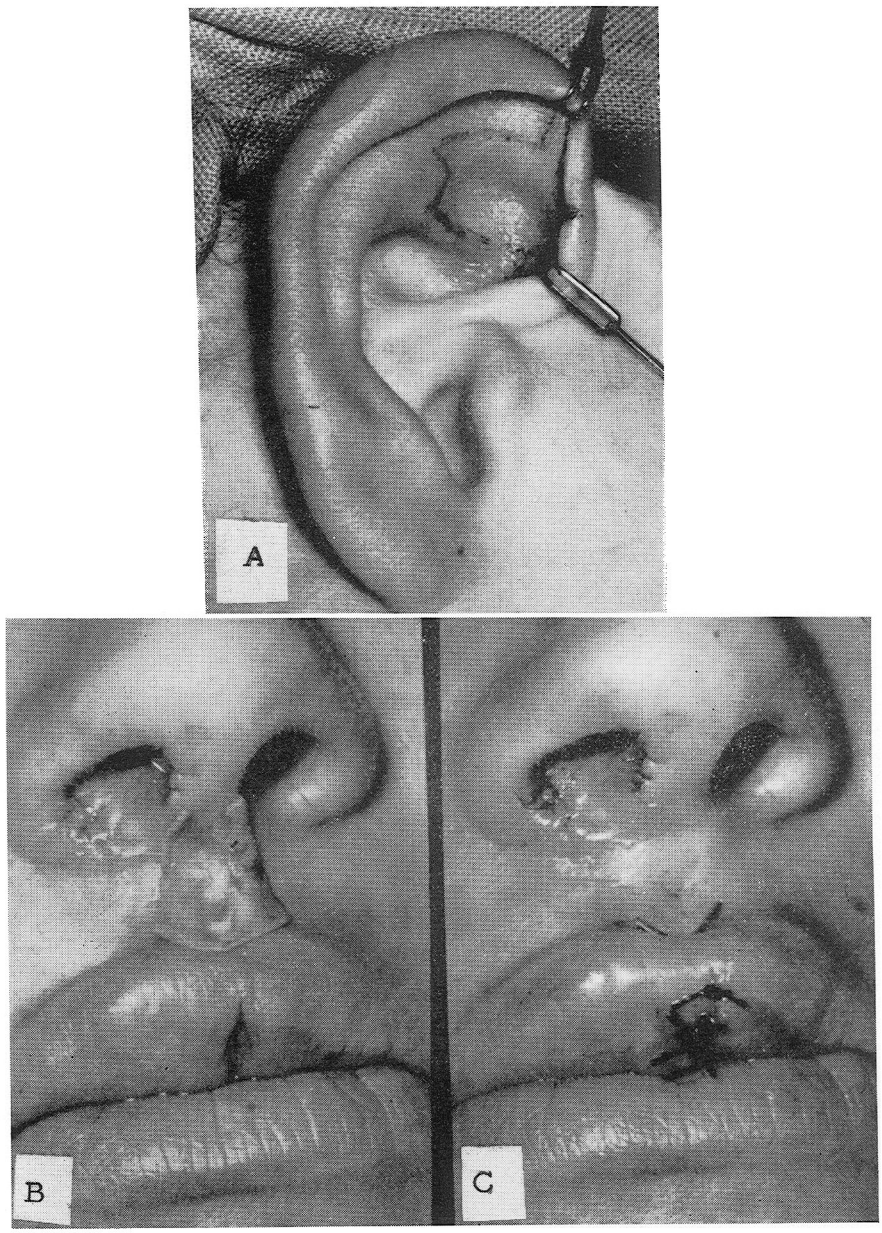

FIGURE 6. Philtrum construction using cartilage from the ear antihelix.

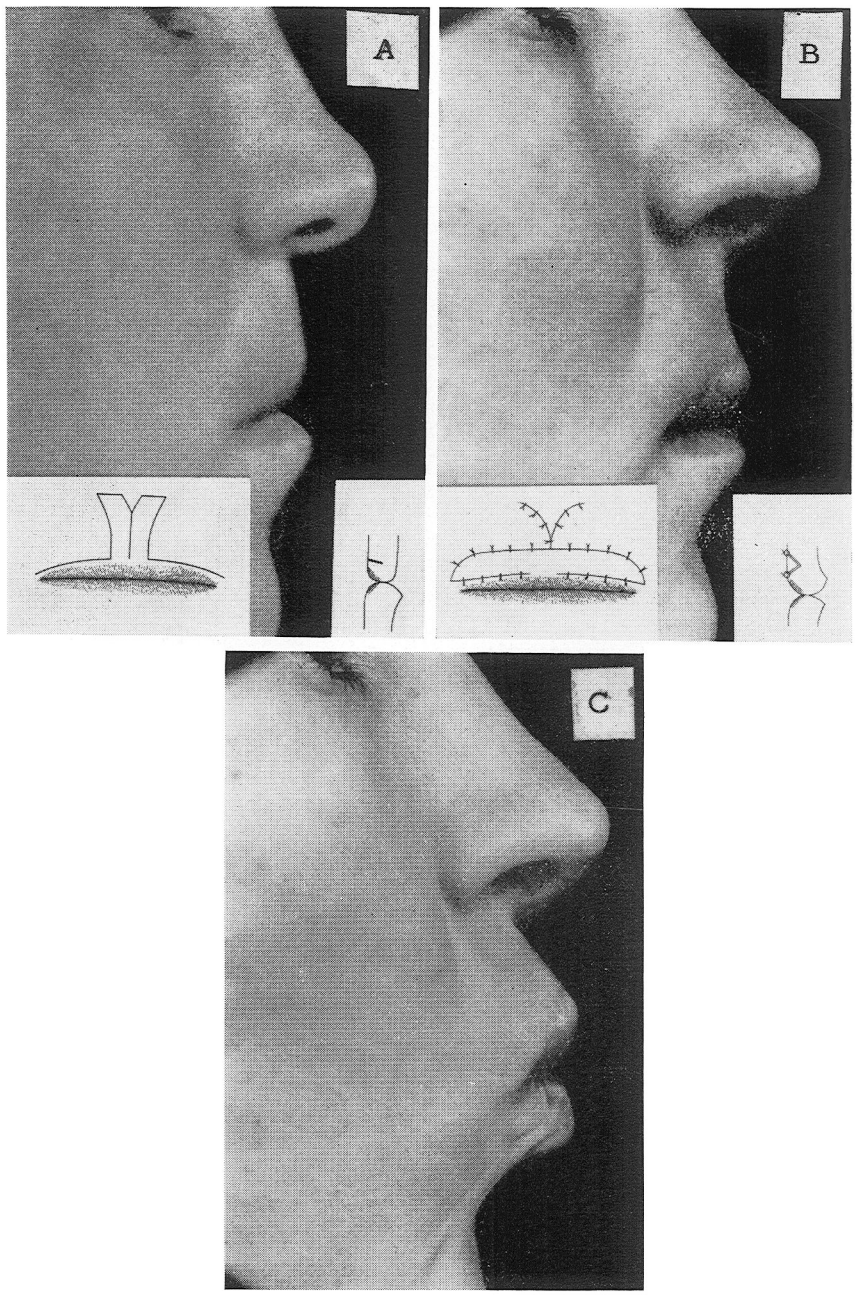

FIGURE 7. Protrusion of oral mucosa utilizing double Z-plasty on the inside of the upper lip (unilateral cleft).

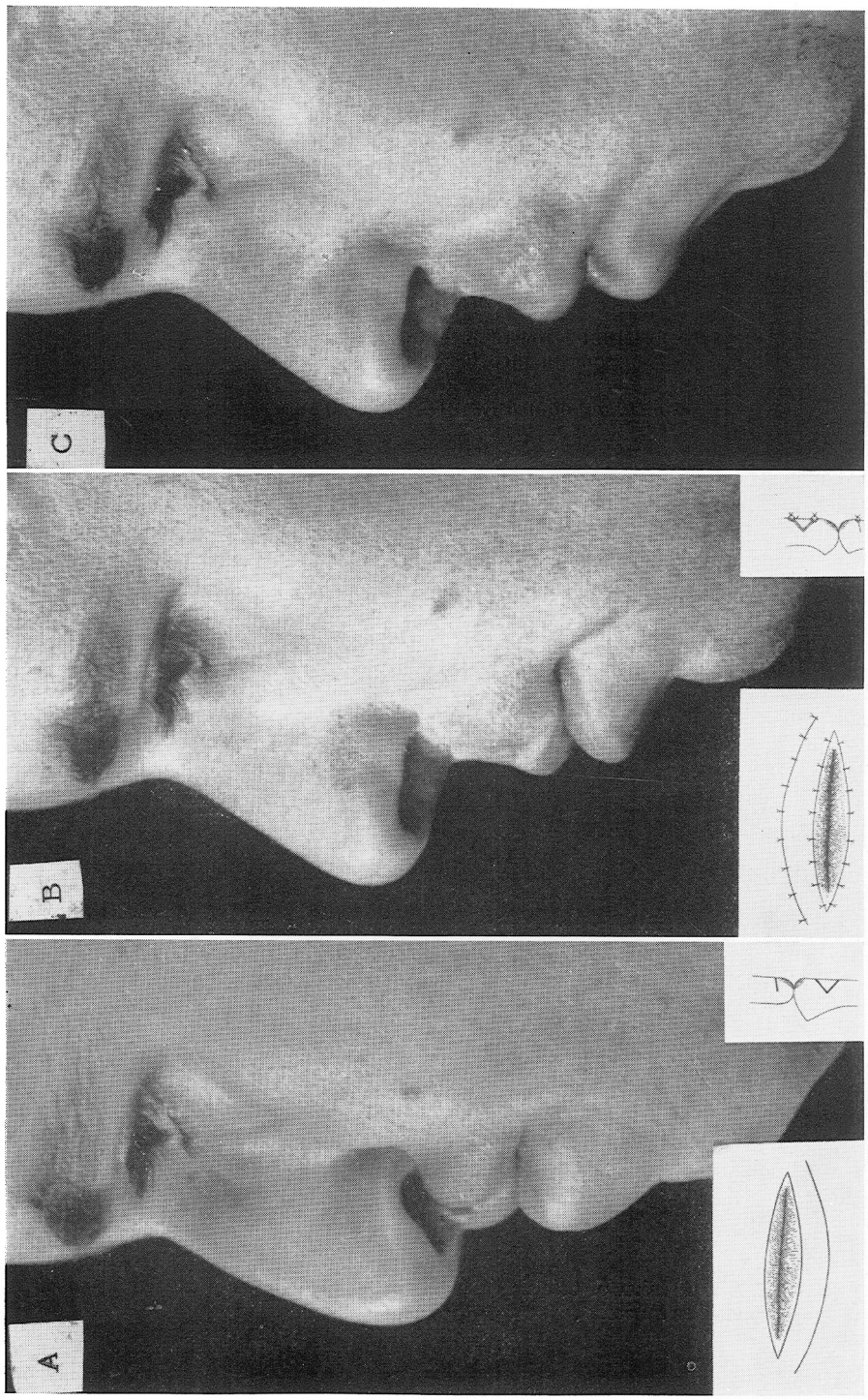

FIGURE 8. Another method of oral mucosal protrusion utilizing visor-flap from lower lip to upper lip (bilateral cleft).

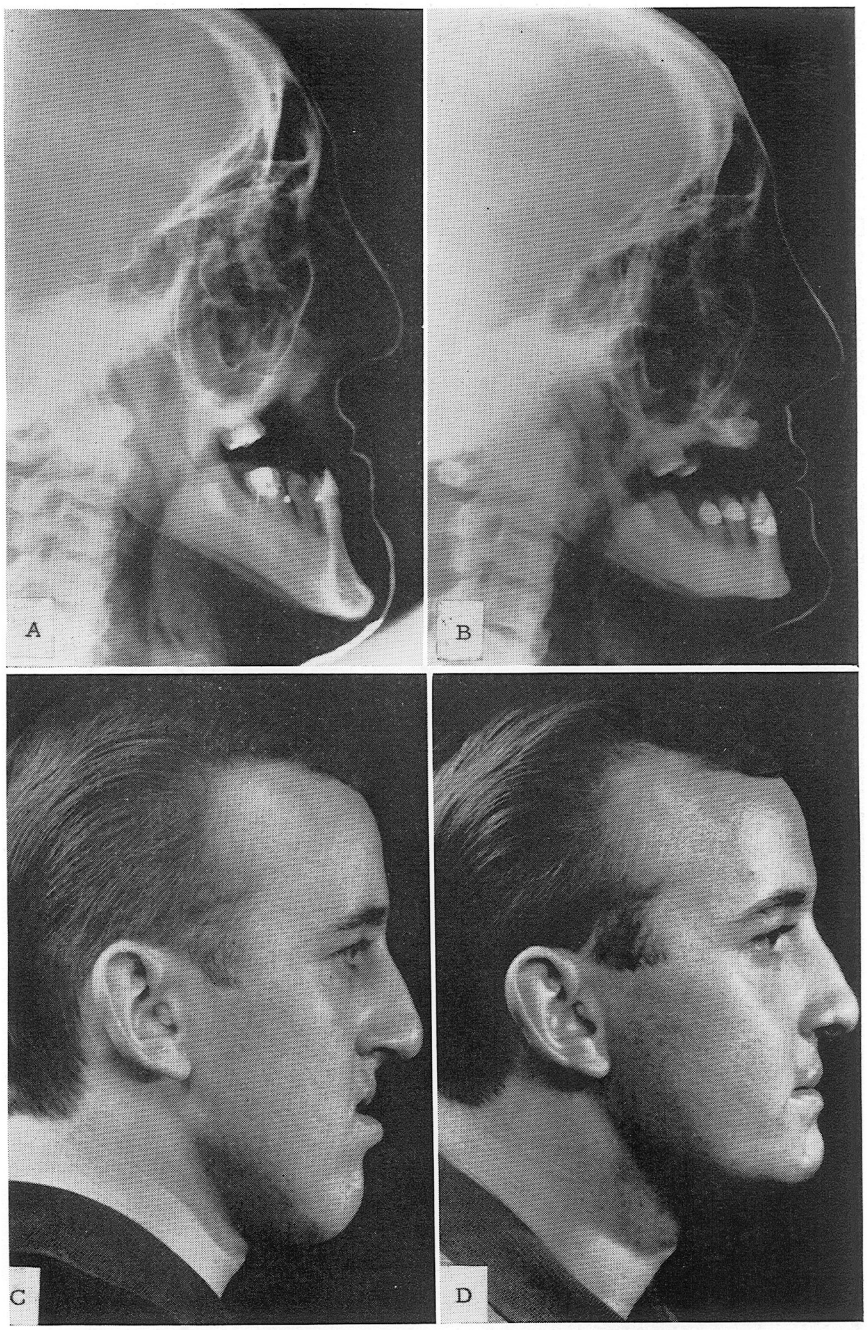

FIGURE 9. Bone transplanted to the maxilla from the chin: X ray and case.

trum construction in the single and double cleft lip, utilizing muscle, subcutaneous tissue, and cartilage.

reprints: *Prof. Dr. Otto Neuner*
Freiburgstrasse 7
3000 Bern
Switzerland

References

1. Brown, J. B., and F. McDowell, *Plastic Surgery of the Nose.* London: Kimpton, 1951.
2. Lexer, E., *Die gesamte Wiederherstellungschirurgie, Bd. I.* Leipzig: J. A. Barth, 1931.
3. Millard, D. R., Jr., A primary camouflage in the unilateral harelip. In *Transactions of the International Congress of Plastic Surgeons.* P. 160. Baltimore: Williams & Wilkins, 1957.
4. Millard, D. R., Jr., Columella lengthening by a forked flap. *Plastic reconstr. Surg., 22,* 454–461, 1959.
5. Neuner, O., Delayed correction of cheilognathopalatoschisis with particular reference to the construction of the philtrum. Excerpta Medica Foundation, *International Congress Series, No. 174.* Pp. 469–474, 1968.
6. Neuner, O., Sekundäre Korrekturmöglichkeiten bei Lippen-Kiefer-Gaumenspalt-Patienten. *Oest. Z. Stomat., 62,* 268–282, 1965.
7. Neuner, O., The functional and cosmetic treatment of cleft lip and palate. Excerpta Medica Foundation, *International Congress Series, No. 141.* Pp. 118–128, 1967.
8. Neuner, O., Zur Rehabilitation der Naseneingangs- und Oberlippenpartie bei LKG-Spaltträgern. *6. Tagung der Deutschen Gesellschaft für Plastische und Wiederherstellungschirurgie,* München, 189–198, 1967.
9. Schmid, E., Die Annäherung der Kieferstümpfe bei Lippen-Kiefer-Gaumenspalten, ihre schädlichen Folgen und Vermeidung. *Fortschr. Kiefer- u. Gesichtschir., 1,* 37–39, 1955.
10. Schmid, E., Wiederherstellungsprobleme im Philtrumbereich der Lippe, unter besonderer Berücksichtigung der Unterentwicklung des Nasensteges. *Dtsch. Zahn-, Mund- u. Kieferheilk, 26,* 397–409, 1957.