

Flexibility in Surgical Planning for Velopharyngeal Incompetence

ERNEST N. KAPLAN, M.D.

RICHARD P. JOBE, M.D.

ROBERT A. CHASE, M.D.

Palo Alto, California

An effective velopharyngeal mechanism can be restored by several techniques: surgical reconstruction, speech training, prosthodontic techniques, or any combination of the three. However, criteria for selection of an appropriate therapeutic program are generally lacking and should be established.

Many surgical procedures are described. Palate pushbacks, pharyngoplasties and pharyngopalatal flaps have many variations and combinations. They are designed to alter the spatial relations of the palate and pharynx so that intact musculature can achieve closure. No single operation is a panacea. Therefore, one must match the operative procedure or other course of management to the individual anatomic, pathologic and psychologic situation. Mazaheri (17) and Porterfield (25) have proposed similar approaches to the problem.

We suggest a method for grouping velopharyngeal incompetent mechanisms and guidelines for their management.

Grouping of Factors Causing Incompetence

The patients are grouped in the following way, according to cause of velopharyngeal incompetence instead of the etiologic condition: active palate with anatomic disproportion, immobile palate, ineffective palate, and inconsistent palate. The size of the palatopharyngeal orifice, range of motion in the palate and pharyngeal wall are the major anatomic factors involved in palatopharyngeal closure (6, 24). Each group includes abnormalities caused by both cleft palate and other noncleft palate conditions (13, 25, 26), including levator paralysis, myopathies, and congenital disproportions of the nasopharynx and palate.

I. ACTIVE PALATE WITH ANATOMIC DISPROPORTION. Three variations are shown in Figure 1/1. In this group there is a relative disproportion

Dr. Kaplan is a Resident in Plastic Surgery and Fellow in Rehabilitation Surgery, Dr. Jobe is a Clinical Assistant Professor of Surgery, and Dr. Chase is Professor and Executive in Department of Surgery, Stanford University School of Medicine.

This study was supported in part by PHS Research Grant DE 01995-04, National Institute of Dental Research.

This paper was presented at the 1967 Annual Meeting of the American Cleft Palate Association, Chicago.

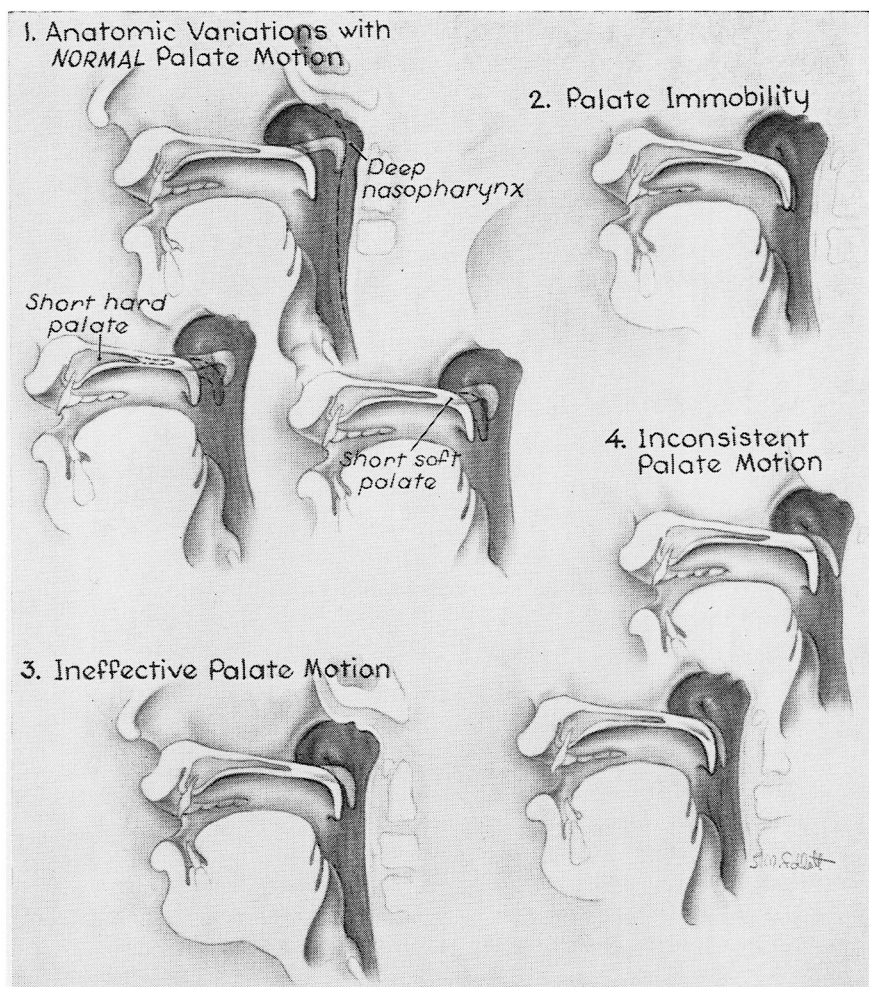


FIGURE 1. Grouping of factors causing velopharyngeal incompetence.

between the palate length and nasopharyngeal depth, but the palate is active with a full range of motion and the site of attempted contact with the pharynx is appropriate (5). The excessive size of the palatopharyngeal orifice results from: short palate (hard or soft), unusual configuration and position of the cranial base and cervical vertebra, inadequate pharyngeal soft tissue (adenoids) or deep nasopharynx (7, 9, 18, 21, 24, 27, 32).

II. IMMOBILE PALATE. Figure 1/2 demonstrates palatal immobility. Levator inactivity can be caused by polio, diphtheria, or other paralytic neurologic diseases, myopathy, or central nervous system impairment (26). Also, inactivity can result from post surgical scar infiltration of the

palate. Despite any of these, pharyngeal wall musculature may function effectively.

III. **INEFFECTIVE PALATE.** As shown in Figure 1/3, the palate does partially elevate but closure is ineffective and incomplete. Ineffective closure can result from inadequate palate tissue, restriction of the palate by scar, partial levator paralysis and palatopharyngeal disproportion or any combination of these. Any or all of these may be found in the repaired cleft palate patient.

IV. **INCONSISTENT PALATE.** Demonstrated in Figure 1/4 is the group of patients who intermittently can achieve velopharyngeal closure but who break down during stressful situations. Included also are those patients who apparently have the necessary anatomy and physiology but have not learned to use the palate properly. This pattern is often seen, hopefully temporarily, after surgery for correction of velopharyngeal incompetence. Immaturity, insufficient speech training, central nervous system disease, psychological disturbance, and deafness may cause inconsistency.

Methods for Determining the Cause of Velopharyngeal Incompetence

The factors causing velopharyngeal incompetence, as outlined above, are determined by combining information from the history, physical examination, dynamic and static respiratory studies, audiometrics, cine-fluorographic voice study, cephalometrics, electromyography and electrical stimulation of the palate and pharynx. Each technique contributes information which leads to appropriate classification.

HISTORY. A history of cerebral trauma, diphtheria, poliomyelitis, or other neurologic infectious disease assists in determining a paralytic etiology of velopharyngeal incompetence. A history of adenoidectomy preceding the onset of hypernasality suggests an anatomical disproportion.

PHYSICAL EXAMINATION. The mobility of the palate and pharynx is, in part, determined by observation and palpation. The amount and distribution of scarring are evaluated. An assessment is made of nasopharyngeal proportions by clinical judgment.

CINEFLUOROGRAPHY. This is one of the most useful tools to measure velopharyngeal incompetence, determining the range of palate motion, and the amount of pharyngeal wall activity.

CEPHALOMETRICS. A stop-frame cephalometric tracing of the cine-fluorographic study shows palate length, nasopharyngeal depth and velopharyngeal gap, both at rest and during maximum palate ascent. This information is helpful in evaluating the possibility of anatomic disproportion.

ELECTROMYOGRAPHY. Electromyography is not routinely used; however, where there is evidence of palate immobility, EMG findings are useful in determining the presence and etiology of any neuromuscular deficits.

ELECTRICAL STIMULATION OF THE PALATE. By observing the response of palatopharyngeal muscles to faradic and galvanic current, we can evaluate the state of innervation and range of motion of each muscle.

AUDIOMETRICS. An audiogram is obtained to determine the presence of hearing problems which may result in inadequate recognition of normal speech and interfere with speech development or training.

RESPIRATORY DYNAMICS. The percent of nasal leak associated with blowing, sucking, and normal and maximal respiration, is determined (6). This measurement gives additional quantitative information about the magnitude of the palatopharyngeal gap, and is useful in sequential post-treatment evaluation.

The Selective Management of Velopharyngeal Incompetence

After the mechanism of velopharyngeal incompetence has been determined, a selective but flexible therapeutic program is outlined.

I. ACTIVE PALATE WITH ANATOMIC DISPROPORTIONS. For patients in this group, the guiding principle is to preserve palate activity without limiting range of motion. Reconstruction is directed toward reducing the size and altering the shape of the nasopharynx (27).

The normal physiologic situation can be approximated by pharyngoplasty, or by implant of cartilage (23) or alloplastic materials (1) in the retropharyngeal area. We have not determined the apparent limit of implant size, but implants with anterior projection of up to 1.5 cm have been successful. Success using the Hynes (15) pharyngoplasty is possibly limited to gaps of less than 5 mm (14). The implant or pharyngoplasty is placed at the point of attempted contact. This usually is near the level of the promontory of the atlas. However, in younger children, the contact point tends to be much above the atlas. As growth occurs, the palate is at a lower level in the nasopharynx and the point of palatal contact is frequently at or below the level of the atlas (16, 31). In the placement of an implant one must consider this growth pattern. Preoperative x-ray study assists in determining proper implant location.

When a large adenoid pad is present or when there is a specific contraindication to surgery of the posterior pharyngeal wall, the alternative to moving the pharynx forward is to push the palate back. The island pedicle flap (12, 18), the nasal mucosal flap (10), or the combined palate pushback and superiorly based pharyngeal flap (22) should be used to cover the raw nasal surface. A previous pushback does not contraindicate a repeat pushback operation. We feel that implantation of flaps into the mobile, muscular, posterior portion of the velum may have an adverse restrictive effect.

II. PALATE IMMOBILITY. The markedly or totally immobile palate, whether due to scarring, neurologic disease or other problems, is not capable of intrinsic elevation against the pharyngeal wall. Therefore, other available muscle units must be used. There are many reports showing a correlation between speech results and a mobile pharynx. Obser-

vations by Moran (19), Skoog (30), Taub (34), Morris and Spriesterbach (20), Bzoch (4), Owsley (22), Randall (26), and others, indicate that pharyngeal activity is an important mechanism for diminishing the nasopharyngeal orifice. A properly placed pharyngeal flap or prosthesis can allow the active pharyngeal wall (superior constrictor and palatopharyngeus) to occlude against the flap and thus achieve pharynx-to-flap closure. Either a superiorly or inferiorly based flap attached to the trailing palate edge can achieve the desired position. However, there is minimal difference in the ultimate flap position because of scar contraction in the raw pharyngeal bed (8, 28, 29). A wide flap is a more efficient obturator; therefore, lining the raw under-surface of the flap as suggested by Owsley and Blackfield (22) may be useful. The flap can be combined with a palate pushback if extra length is required.

For patients with immobility of both the pharyngeal wall and palate, reduction of nasal leak with speech may be achieved by an operative procedure that narrows the nasopharyngeal orifice. Speech results, however, may be disappointing.

III. **INEFFECTIVE PALATE.** This group of patients includes many who have had previous cleft palate repair. Ineffective palate elevation can be caused by short palate with inadequate tissue, limitation by scar, partial levator paralysis or relatively deep nasopharynx or any combination of these. In these patients a combined pushback and superiorly-based pharyngeal flap (figure 2) attached to the raw nasal surface of the mucoperiosteum of the hard palate, offers a satisfactory reconstruction. The operation is designed to reposition and reinforce the limited palate motion. The pushback brings the palate closer to the pharyngeal wall. The anteriorly-attached flap lines the raw nasal surface, prevents scar contraction, thus preventing contraction and preserving the length of the pushback. Also the flap suspends the palate closer to the pharyngeal wall reducing the distance the palate must traverse. This favorable repositioning is not possible from pushback alone. It is important to emphasize that placement of the flap into the raw nasal surface is anterior to the levator insertion and does not significantly restrict the palate. There is not adequate evidence that the pharyngeal flap is a "dynamic" (2) aid to palate elevation. The flap is based above the point of expected pharyngeal contact as located by preoperative x-ray study. Additional advantages of the procedure are: the pharynx circumference is narrowed by the width of flap donor site, the contracture of the flap further diminishes the nasopharyngeal port, and the flap partially obstructs the nasopharynx. The results of the combined pushback and superiorly-based flap are quite gratifying and have been published (3, 11).

Many other operative procedures have been suggested for this group of patients with improvement in speech reported. We have been disappointed, however, by pharyngeal flaps attached to the trailing edge of

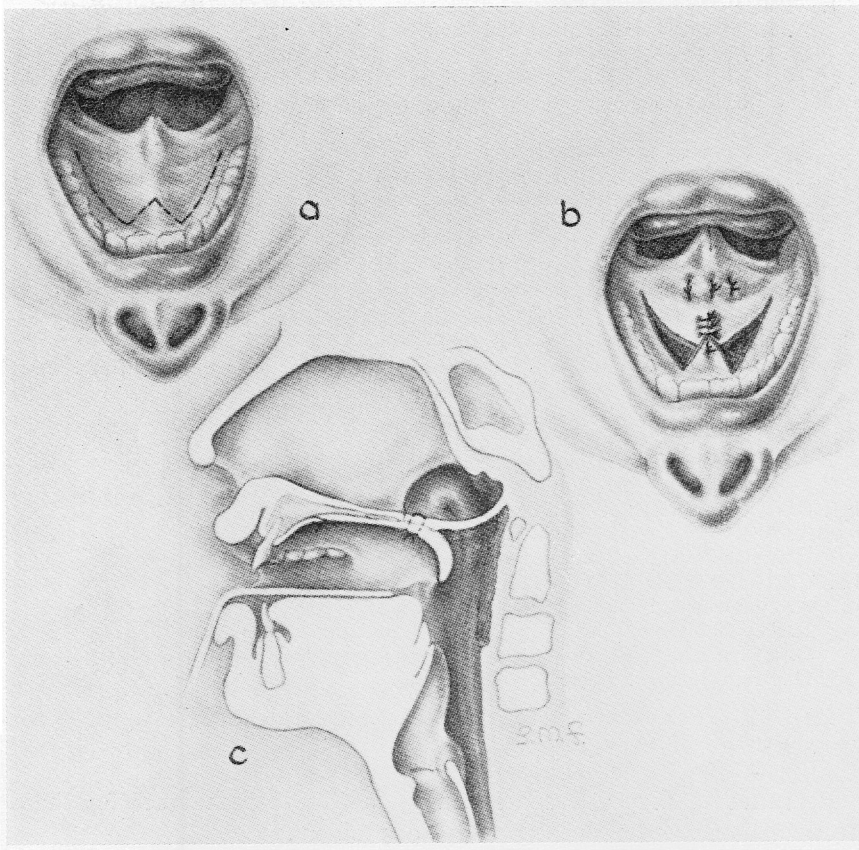


FIGURE 2. The palatal pushback combined with a superiorly-based pharyngeal flap. Note the relation of the flap as attached to the raw nasal surface, anterior to the mobile portion of the palate.

the palate, whether superiorly or inferiorly based, because they tend to tether the palate downward, restricting its normal elevation (22, 33).

IV. INCONSISTENT PALATE. There are some patients who are intermittently capable of achieving velopharyngeal closure but, in spite of this, have hypernasality. Generally, these are young children or those who have had insufficient speech training. There is evidence of closure of the velum on cine film, speech analysis and respiratory study during controlled laboratory conditions, but breakdown of speech occurs during the emotional stress of social conversation. Before surgery is advised, these patients should have intensive speech therapy for an extended period.

Other individuals with central nervous system damage cannot coordinate the velum and other speech structures even though the anatomy is normal. This poses a challenging problem for the speech pathologist.

- I. *GROUP ONE: ACTIVE PALATE ANATOMIC DISPROPORTION*
 - A. Relatively small gaps (less than 1 cm)
 1. *No Adenoids*
 - a. Retropharyngeal implant (cartilage, alloplastics)
 - b. Palate pushback with superiorly based pharyngeal flap
 - c. Pharyngoplasty
 2. *Adenoid Pad Present*
 - a. Pushback with lining of nasal surface
 - b. Palate pushback with superiorly based flap
 - c. Island pedicle flap
 - d. Nasal mucosal flap
 - B. Large Gaps (greater than 1 cm)
 1. Palate pushback with superiorly based flap
 2. Palate pushback with retropharyngeal implant
- II. *GROUP II: IMMOBILE PALATE (LEVATOR PARALYSIS)*
 - Active Pharynx (palatopharyngeus and/or superior constrictor is functioning)
 1. Pharyngeal flap attached to trailing edge of palate
 - a. Superiorly based flap
 - b. Inferiorly based flap
 - c. Inferiorly based flap with palate pushback
 - d. High superiorly based flap
- III. *GROUP THREE: INEFFECTIVE PALATE*
 - A. *Short Palate, inadequate tissue, or disproportion*
 - Palate pushback with superiorly based flap
- IV. *GROUP FOUR: INCONSISTENT PALATE*
 - A. Immaturity: Time and speech training
 - B. Psychologic problem: Time and psychologic investigation
 - C. Hearing loss: Hearing correction and speech training
 - D. Brain damage: Speech training

FIGURE 3. Summary of therapeutic management according to type of velopharyngeal incompetence.

Presented in Figure 3 is a summary outline of techniques for therapeutic management according to type of problem.

Summary

Hypernasality resulting from velopharyngeal incompetence is a symptom of any of a number of diverse, anatomic, pathologic, and psychologic abnormalities. A method of classification of these abnormalities is given and guidelines for their management are suggested.

reprints: *Dr. Ernest N. Kaplan*

Department of Surgery

Stanford University School of Medicine

300 Pasteur Drive

Palo Alto, California 94304

References

1. BLOCKSMA, R., Correction of velopharyngeal insufficiency by silastic pharyngeal implant. Presented at the annual meeting of the Society of Plastic and Reconstructive Surgery, Hawaii, October, 1962.
2. BROADBENT, T., and C. SWINYARD, The dynamic pharyngeal flap. *Plastic reconstr. Surg.*, **23**, 301-311, 1959.
3. BUCHHOLZ, R. B., R. A. CHASE, R. P. JOBE, and H. SMITH, The use of the com-

- bined palatal pushback and pharyngeal flap operation: a progress report. *Plastic reconstr. Surg.*, 39, 554-561, 1967.
4. BZOGH, K. R., Clinical studies of the efficacy of speech appliances compared to pharyngeal flap surgery. *Cleft Palate J.*, 1, 275-286, 1964.
 5. CALNAN, J., The mobility of the soft palate: a radiological and statistical study. *Brit. J. plastic Surg.*, 14, 33-38, 1961.
 6. CHASE, R. A., An objective evaluation of palatopharyngeal competence. *Plastic reconstr. Surg.*, 26, 23-29, 1960.
 7. COCCARO, P., J. DANIEL SUBTELNY, and S. PRUZANSKY, Growth of soft palate in cleft palate children. *Plastic reconstr. Surg.*, 30, 43-55, 1962.
 8. CONWAY, H., Combined use of the pushback and pharyngeal flap procedures in the management of complicated cases of cleft palate. *Plastic reconstr. Surg.*, 7, 214-224, 1951.
 9. COUPE, T. B., and J. DANIEL SUBTELNY, Cleft Palate—Deficiency or displacement of tissue. *Plastic reconstr. Surg.*, 27, 600-612, 1960.
 10. CRONIN, T., Method of preventing raw area on nasal surface of soft palate in pushback surgery. *Plastic reconstr. Surg.*, 20, 474-484, 1957.
 11. DIBBELL, D., D. LAUB, R. JOBE, and R. A. CHASE, A modification of the combined pushback and pharyngeal flap operation. *Plastic reconstr. Surg.*, 36, 165-172, 1965.
 12. EDGERTON, M., The island flap pushback and the suspensory pharyngeal flap in surgical treatment of the cleft palate patient. *Plastic reconstr. Surg.*, 36, 591-630, 1965.
 13. FLETCHER, S. G., Hypernasal voice as an indication of regional growth and developmental disturbances. *Logos*, 3, 3-12, 1960.
 14. GYLLING, U., and A. I. SORVIO, Pharyngoplasties: in the light of the follow-up of 106 operated patients. *Transactions of International Congress of Plastic Surgery*, 66, 229-231, 1963.
 15. HYNES, W., Pharyngoplasty by muscle transplantation. *Brit. J. plastic Surg.*, 3, 128-135, 1950.
 16. KING, E. W., A roentgenographic study of pharyngeal growth. *Angle Orthod.*, 22, 23-37, 1952.
 17. MAZAHERI, M., R. T. MILLARD, and D. M. ERICKSON, Cineradiographic comparison of normal to noncleft patients with velopharyngeal inadequacy. *Cleft Palate J.*, 1, 199-209.
 18. MILLARD, D. R., Wide and/or short cleft palate. *Plastic reconstr. Surg.*, 29, 40-56, 1962.
 19. MORAN, R., The pharyngeal flap operation as a speech aid. *Plastic reconstr. Surg.*, 7, 202-213, 1951.
 20. MORRIS, H. L., and D. C. SPIRSTERSBACH, The pharyngeal flap as a speech mechanism. *Plastic reconstr. Surg.*, 39, 66-70, 1967.
 21. MOSS, M. D., Malformations of the skull base associated with cleft palate deformity. *Plastic reconstr. Surg.*, 17, 226-234, 1956.
 22. OWSLEY, J., and H. BLACKFIELD, The technique and complications of pharyngeal flap surgery. *Plastic reconstr. Surg.*, 35, 531-539, 1965.
 23. PERTHES, H., Beitrag zur Behandlung von Gaumenspalten. Diss. Tübingen, 1912 (quoted by Nylen, 1961).
 24. PODVINEC, S., The physiology and pathology of the soft palate. *J. Laryng. Otolaryng.*, 66, 452-461, 1952.
 25. PORTERFIELD, H. W., J. TRABUE, J. TERRY, and R. STIMPERTY, Hypernasality in non-cleft palate patients. *Plastic reconstr. Surg.*, 37, 216-220, 1966.
 26. RANDALL, P., F. BAKES, and C. KENNEDY, Cleft palate-type speech in the absence of cleft palate. *Plastic reconstr. Surg.*, 25, 484-495, 1960.
 27. RICKETTS, R. M., The cranial base and soft structures in cleft palate speech and breathing. *Plastic reconstr. Surg.*, 14, 47-61, 1964.
 28. ROSENTHAL, W., Vur Farge der Gaumenplastik, *Zbl. Chir.*, 51, 1621-1624, 1924.
 29. SCHOENBORN, K., Ueber eine neue Methode der Gaumenplastik. *Arch. klin. Chir.*, 20, 527-531, 1876.
 30. SKOOG, T., The pharyngeal flap operation in cleft palate. *Brit. J. plastic Surg.*, 18, 265-282, 1965.

31. SUBTELNY, J. DANIEL, A cephalometric study of the growth of the soft palate. *Plastic reconstr. Surg.*, 19, 49-62, 1957.
32. SUBTELNY, J. DANIEL, and H. K. BAKER, The significance of adenoid tissue in velopharyngeal function. *Plastic reconstr. Surg.*, 17, 235-250, 1956.
33. SULLIVAN, D., Bilateral pharyngoplasty as an aid to velopharyngeal closure. *Plastic reconstr. Surg.*, 27, 31-39, 1961.
34. TAUB, S., The Taub oral penendoscope: a new technique. *Cleft Palate J.*, 3, 328-346, 1966.