

Neonatal Orthopedic Correction for Cleft Lip and Palate Patients: A Preliminary Report

F. R. SHIERE, D.D.S.
J. H. FISHER, M.D.
Boston, Massachusetts

For the past few years, attention to the treatment of cleft lip and palate problems has been directed toward early care, beginning at birth or shortly thereafter. If one is to focus his attention on this abnormality, the work of Dr. McNeil (5) in Glasgow and Dr. Burston (1-4) in Liverpool must be studied. Credit is given to Dr. McNeil for initiating the concept of early orthopedic care for the newborn, while modifications and additional basic investigations have developed from the research of Dr. Burston and others.

Burston (4) has reported that in the absence of orthopedic correction, surgery tends to perpetuate the malrelationship of the segments. At a later date, teeth erupt in malocclusion and a profound effect is produced on the alveolus with the development of gross problems of the maxillary arch.

The authors and other members of the Tufts University Cleft Palate Institute team became interested in the early care concept following the recall of approximately 120 patients who had been treated surgically over the past 10 years for cleft lip and palate at the Boston Floating Hospital. The surgical repairs were satisfactory, but examination of the study casts revealed deviations of maxillary arch form in a high percentage of cases (an example is shown in Figure 1). These findings coincide with the statements of Dr. Burston. Many of the patients recalled are presently receiving prolonged orthodontic treatment at the Institute. In light of all this, it also seemed logical to take advantage of both appositional and sutural growth in the nasomaxillary complex during a period of maximum potential.

The purpose of this preliminary investigation is to study the effect of using an orthopedic appliance in newborns and to determine immediate advantages or disadvantages of the use of the appliance to maxillary arch alignment, feeding, surgery, and parent-child relationships. Also evaluated, at a later time, will be the muscular development, swallowing habits, mas-

Presented at the 1963 Convention of the American Cleft Palate Association, Washington, D. C.

Dr. Shiere is Director, Tufts University Cleft Palate Institute in Boston. Dr. Fisher is Pediatric Surgeon-in-Chief, Boston Floating Hospital.

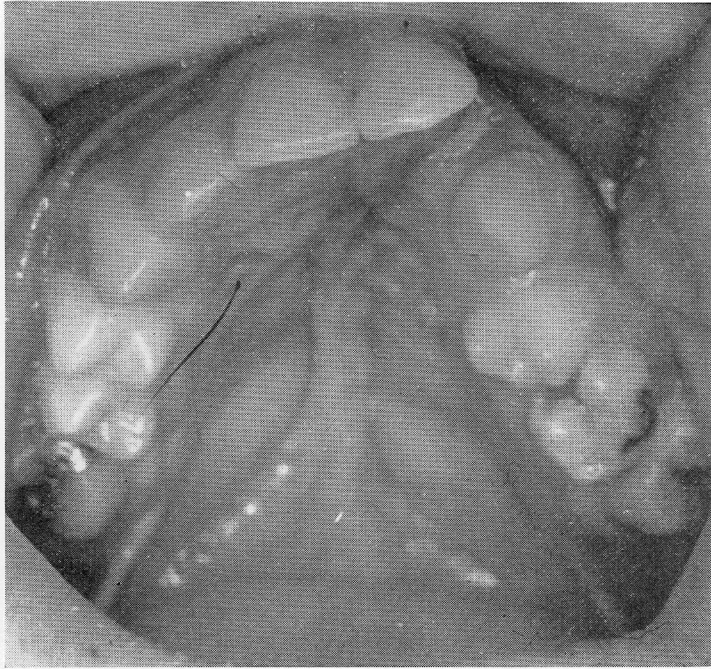


FIGURE 1. An example of successful palate closure but with deviation of left maxillary segment.

tication, speech and hearing problems, caries attack rate, the alignment and occlusion of the permanent dentition, and the general physical growth and development of these children.

Method

To date, a total of nine cleft lip and palate patients have been started on this pilot program. Using Stark's (6) classification system which is based on embryological development, our series includes two cases of primary palate, five cases of secondary palate, and two cases of combined lip and palate abnormalities. The five cases of secondary cleft palate were included to study particularly the effect of the orthopedic appliance on the problems of feeding, soft palate surgery, and the parent-child relationships, as well as the effect on later development.

All patients were seen at the Boston Floating Hospital as soon after birth as possible. Referrals were made either to the Hospital or to the Institute, but all were housed in the Hospital. Following a complete physical examination of the child's general health, and in the absence of complications, treatment was instituted as early as three days after birth.

Since there were no commercial impression trays available in this extremely small size, an assortment of maxillary and mandibular trays were made in acrylic prior to the initiation of this pilot study. Impressions from

several hospitalized babies with problems other than oral ones were used as models.

Although dental compound has been used as the preferred impression material for cleft palate patients, the authors have found that the alginates are most accurate, easy to manipulate, and safe. Initially, the impressions were taken in the operating room area in order to avoid respiratory difficulties and other possible hazards; now they are taken outside the operating room area. All the necessary precautions are observed (good lighting, an aspirator, oxygen, mouth mirror, and a pair of cotton pliers).

A working model is obtained from the master model. With a jig saw, the cast is cut through the area of the cleft. These segments are then realigned, with the shorter lateral segment moved approximately 3 mm forward and/or laterally. A mix of stone is then poured into the void, including the cleft area over the alveolar ridge, and allowed to set. Double thick pink wax is adapted to the new working model, and wing extensions for extra-oral anchorage are also constructed. Soft red wax is utilized over the posterior alveolar ridge area. The wax model is then tried in the mouth, a mandibular relationship is registered in the softened red wax, and adjustments are made if necessary. The final wax model is then invested, processed in clear acrylic by heat curing, and polished (Figure 2).

Within 24 hours after the initial impressions, the appliance is inserted. String is threaded through the openings in the wings and taped to the

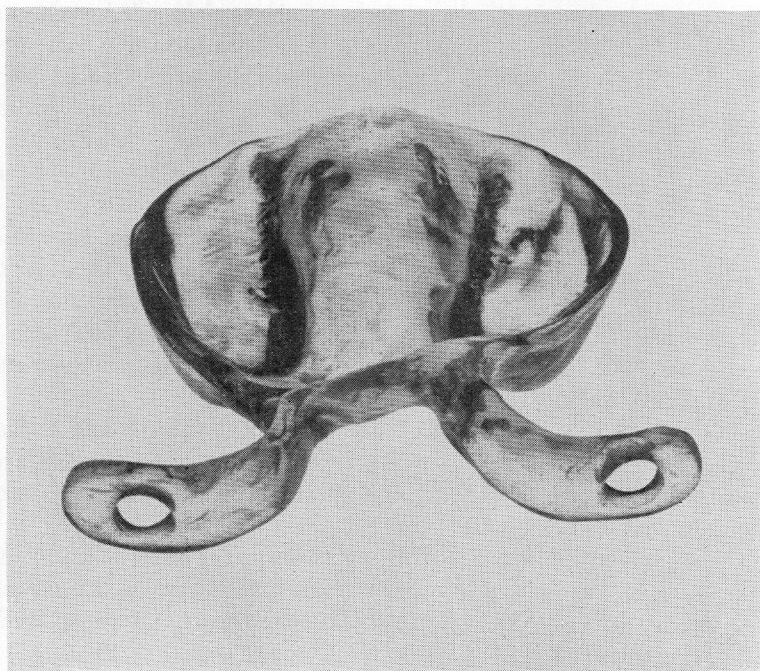


FIGURE 2. Orthopedic appliance fabricated in clear acrylic.

cheeks of the infant. The extraoral anchorage provides adequate retention and the babies have been able to keep the appliance in place for 23 hours a day. It is removed for one hour during the day for relaxation.

We have found it necessary to keep the infant in the hospital for an additional 24 to 48 hours to relieve sore spots or gagging, to allow the baby to become accustomed to the appliance, and to observe the feeding procedures and adaptability. With the appliance in place, all babies are bottle fed as normal children. Best results are achieved with a long, soft nipple, and if necessary the size of the aperture is enlarged. Before discharge, the mother is instructed in the proper care and handling of the appliance and has the opportunity to feed the baby several times before taking it home.

Return appointments are made at three week intervals to change the appliance in order to prevent any constriction of growth. These procedures are done on an out-patient basis.

Discussion

As stated earlier, the primary objectives to the neonatal orthopedic care of the newborn cleft palate patient are the restoration of maxillary arch form by means of forward and lateral movements of the underdeveloped maxillary segments and to gently restrain the precocity of the premaxilla. With this technique, it is advantageous to close the lip at a later date. The lateral maxillary plate is thus allowed to move unimpeded from pressures exerted either from the premaxilla or from an early surgically closed lip. Two cases of primary cleft palate have proceeded to the initial completion stage: i.e., an acceptable maxillary arch form has been created and the lip and alveolar clefts have been closed surgically. Following surgery, the appliance was replaced immediately to avoid the possibility of arch collapse and in order to continue normal feeding. However, it now became necessary to remove the anterior segment of the appliance to allow lip pressure to mold the maxillary segments into final approximation.

Five cases with secondary palatal problems, but with good arch form, are currently under treatment. A similar appliance has been used for these cases primarily for natural feeding, muscular stimulation, and proper tongue placement. It is hypothesized from the preceding activities that these children will have improved speech function and normal physical growth and development.

Two cases with cleft lips and palates (one unilateral and one bilateral) are under treatment. Although some progress has been made, it is apparent that these cases are proceeding at a slower rate. It is too early to draw any definite conclusions about them.

Since the conventional treatment has stressed the early closure of the cleft lip, it became necessary to explain to the parents in detail the reasons for delayed lip surgery. The parents accepted the explanations and cooperated wholeheartedly.

Indirectly, benefits have been derived from this postponement. At the time of closure it was noted by the surgeon that more tissue was available

for repair, an increased blood supply assured better healing, and the anesthetic risk was reduced. The alignment of the maxillary segments reduced the tension on the lip closure. Undoubtedly all these factors contributed to the simplification of the surgical problems and resulted in a better appearance.

At this early stage, the one outstanding revelation was the change in attitude of the parents, especially the mothers, toward the child. Tisza (7) has discussed the parental anxieties and the mounting feeding problems and frustrations associated with the newborn child with cleft palate. She stated that in most cases the babies remained in the hospital until the lip was closed; feeding was not a pleasurable and relaxed experience; and the babies had little body contact with the mother during feeding; and the interaction between the mother and child was altered from the beginning of the relationship.

In the nine cases now under care and using the orthopedic appliance, normal bottle feeding occurred almost simultaneously with its insertion. Since surgery was not planned immediately, the child was discharged from the hospital. Only minimum difficulties were experienced during feeding times, and so tensions and frustrations did not arise. A close, loving contact developed between the child and mother. Because of her contribution to the child's well being, feelings of guilt relating to the deformity were perhaps attenuated. In addition the mother felt that she was actually participating in the professional care for the improvement of her child.

Frequent appointments were necessary for observations and appliance therapy, and soon it was noticed that unplanned "group therapy" developed among the mothers in the waiting room. With the help of the social worker these discussions were encouraged and resulted in a mutual exchange of experiences, ideas, and support. One mother in particular emerged as a leader since she had had an older child with a cleft palate and could relate her difficulties and past experiences.

We have found that all newborn cleft palate patients are not suitable subjects for early orthopedic correction. The absence of sucking reflex, or the presence of more severe congenital anomalies (such as heart) clearly appear to be contra-indications for early treatment. Also, when the cleft involves only the soft palate and a small part of the hard palate and where feeding is not a problem, there is no necessity for this type of treatment. In addition to the nine cases presently under care, three cases of the latter type have been followed since birth and will be evaluated in the future.

Illustrative Case Reports

Various stages of treatment are shown for Baby J.L. in Figure 3. Stages of treatment are shown for Baby M.O. in Figure 4.

Summary

A study has been undertaken to determine the value of the neo-natal orthopedic correction of cleft lip and palate patients. Maxillary arch align-

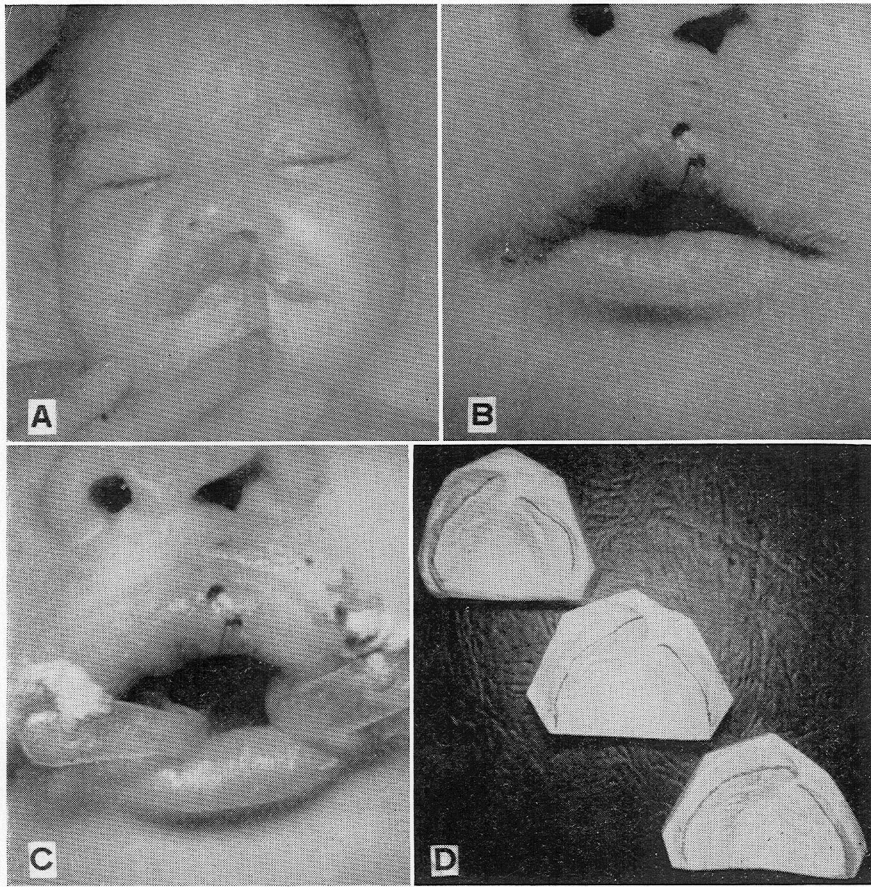


FIGURE 3a. Baby J.L., prior to lip surgery.

FIGURE 3b. Baby J.L., immediately after lip surgery.

FIGURE 3c. Baby J.L., orthopedic appliance in position for normal function and retention.

FIGURE 3d. Baby J.L., study casts (left to right) from five days to six months after insertion of appliance.

ment has been completed in two cases of primary cleft palate. Two cases of combined cleft palate are still under treatment. From a total of nine cases, five patients are using the appliance for feeding, muscle stimulation and restricted tongue placement. All subjects have been able to adjust to normal bottle feeding within 24 to 48 hours after insertion of the appliance. Following initial adjustments to the appliance, all patients were treated on an out-patient basis, until the time of surgical lip closure (when needed). The postponement of lip surgery was not objectional to the parents and was an advantage to the surgical procedure. Initial observations of the

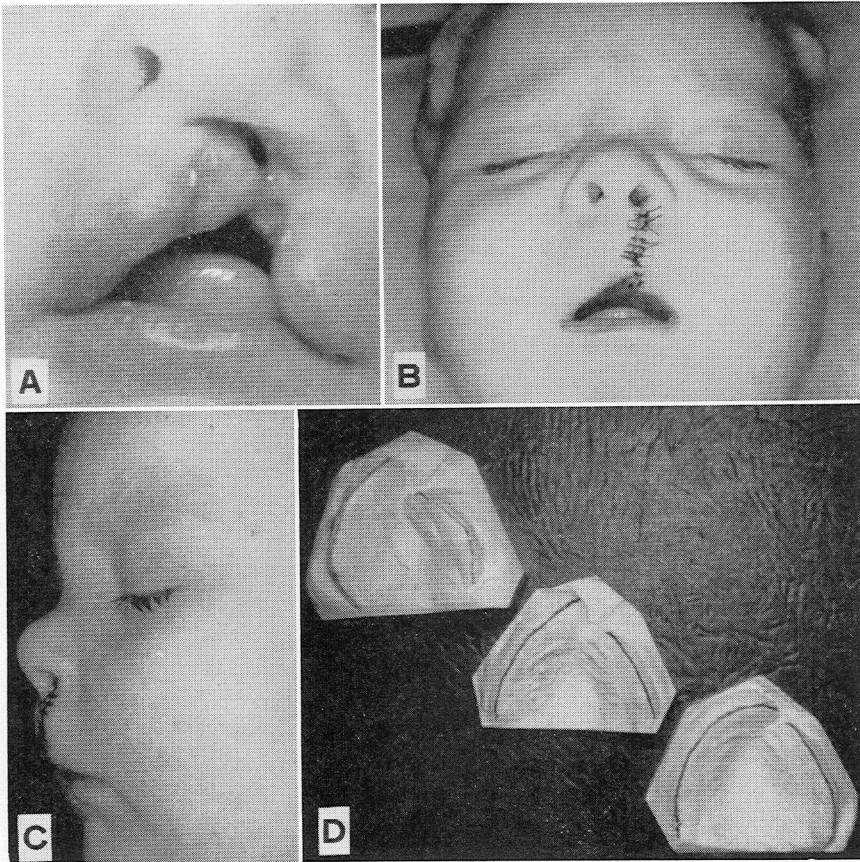


FIGURE 4a. Baby M.O., prior to lip surgery.

FIGURE 4b. Baby M.O., immediately after lip surgery, anterior view.

FIGURE 4c. Baby M.O., immediately after lip surgery, lateral view.

FIGURE 4d. Baby M.O., study casts (left to right) from four days to six months after insertion of appliance.

parent-child relationships demonstrated a relaxation of tensions, a feeling of accomplishment, and a better adjustment to this abnormality when compared with the conventional approach.

*136 Harrison Avenue
Boston Massachusetts*

Acknowledgments: The authors wish to acknowledge the assistance and advice of Dr. Ronald Abrams, pediatric dental intern, Boston Floating Hospital for Infants and Children; to Dr. Russi Gheewalla, orthodontist to the Tufts University Cleft Palate Institute; and to Dr. Helmi R. Fogels for assistance in the preparation of the manuscript.

References

1. BURSTON, W. R., The development of cleft lip and palate. *Annals Royal College of Surgeons*, 25, 225, 1959.
2. BURSTON, W. R., The early orthodontic treatment of cleft palate conditions. *Dent. Pract.*, 9, 41, 1958.
3. BURSTON, W. R., The pre-surgical orthopedic correction of the maxillary deformity in clefts of both primary and secondary palate. *Transactions of the International Society of Plastic Surgeons, Second Congress, 1959*. Baltimore: The Williams & Wilkins Co., p. 28, 1960.
4. BURSTON, W. R., KERNAHAN, D. A., and STARK, R. B., A morphological basis for the analysis and treatment of the cleft lip and palate conditions. *Transactions of the International Society of Plastic Surgeons, Second Congress, 1959*. Baltimore: The Williams & Wilkins Co., p. 9, 1960.
5. MCNEIL, C. K., *Oral and Facial Deformity*. London: Sir Issac Pitman & Sons, Ltd., 1954.
6. STARK, R. B., Embryology, pathogenesis and classification of cleft lip and cleft palate. In S. Pruzansky (Ed.), *Congenital Anomalies of the Face and Associated Structures*. Springfield: Charles C Thomas, 1961.
7. TISZA, VERONICA, and GUMPERTZ, E., The parents reaction to the birth and early care of children with cleft palate. *J. Pediat.*, 30, 86, 1962.