

Facial Musculoskeletal Asymmetry in Hemifacial Microsomia

JEFFREY L. MARSH, M.D.
DAN BACA, B.A.
MICHAEL W. VANNIER, M.D.

Computer-assisted medical imaging—transaxial computed tomography (CT) scans and three-dimensional surface reconstructions—was used to study the muscles of mastication and their osseous origins and insertions in 24 patients with untreated unilateral hemifacial microsomia (HFM). The relationship between the volume of a muscle of mastication and the shape and size of its origin and insertion in such patients varies widely. Comparison of mean volumes of specific muscles documents a statistically significant decrease among patients who have moderate to marked mandibular dysmorphism as compared with those with minimally dysmorphic mandibles. This study supports the hypothesis that the shape and size of the mandible are related to the muscles that originate and insert upon it. However, the variation among individual patients means that assumptions regarding muscle mass and, in turn, function cannot be made regarding an individual patient on the basis of osseous dysmorphism that has been demonstrated on skull radiographs alone.

KEY WORDS: *hemifacial microsomia, facial asymmetry, computed tomography, three-dimensional reconstruction, mandible, muscle*

The functional matrix theory postulates that the mass and shape of bone are dependent on the soft tissue milieu in which the bone resides (Moss, 1960). Anomalies of both muscle and bone have been reported in patients with hemifacial microsomia (Grabb, 1965; Converse et al, 1973; Figueroa and Pruzansky, 1982; Murray et al, 1984; Vargervik and Miller, 1984; Mulliken and Kaban, 1987). Study of the muscles and bones of this craniofacial anomaly, therefore, might assist assessment of the validity of the functional matrix theory. We examined the muscles of mastication and their corresponding skeletal units in patients with untreated unilateral hemifacial microsomia. The objectives of the study were (1) to evaluate qualitatively and quantitatively the degree of dysmorphism of the mandible as well as the individual origins and insertions for each of the muscles of mastication; (2) to evaluate quantitatively the volumes of the muscles of mastication; and (3) to compare the magnitude of bilateral muscle mass asymmetry with the degree of the corresponding skeletal dysmorphism to determine their relationship.

Twenty-four patients who had both unilateral hemifacial microsomia (Gorlin and Pindborg, 1964) and a pretreatment CT scan suitable for volumetric analysis and three-dimensional surface reformation (Marsh and Vannier, 1988;

Vannier et al, 1988) were subjects for this study. All patients were followed through the Cleft Palate and Craniofacial Deformities Institute, Washington University Medical Center, St. Louis, MO. Of these patients, the mean age was 10.7 years with a range between 1 month and 36 years and a standard deviation of ± 9.8 years. Seventy percent (N=17) of the patients were male. The clinically affected side was equally distributed between right (N=12) and left (N=12).

The primary data source was high resolution thin slice CT scans that were reformatted into three-dimensional osseous surface images. The scan images represented 2-mm thick, contiguous, nonoverlapping slices. The scans were obtained and archived to floppy discs on either a Siemens DR-H or Somatom 2 CT scanner with a 256 \times 256 matrix size. The transaxial images were processed in the Mallinckrodt Institute of Radiology's computer assisted imaging center.

The plane of scanning was parallel to the orbitomeatal line. The majority of patients were scanned from the caudal edge of the mandibular symphysis through the plane, including a line 2 cm cephalad to the superior orbital rims. A few younger patients had their entire head scanned. Each scan produced between 50 and 120 transaxial slices. Sedation was required for scans of younger patients. Intravenous Nembutal was used for patients with stable airways; general anesthesia with endotracheal intubation, was used for the few patients, as outpatients, with risk for upper airway obstruction. Oral chloral hydrate was frequently administered to older patients to ensure a high quality scan with minimal motion artifact.

The transaxial scans were used to evaluate quantitatively the volumes of the muscles of mastication using slice-

Drs. Marsh and Baca are from the Division of Plastic Surgery and Dr. Vannier is from the Department of Radiology, Washington University School of Medicine, St. Louis, MO.

Presented in part at the 45th Annual Meeting of the American Cleft Palate Association, Williamsburg, VA, 29 April 1988.

Reprint requests: Jeffrey L. Marsh, M.D., Cleft Palate and Craniofacial Deformities Institute, 400 S. Kingshighway, St. Louis, MO 63110.

by-slice region of interest outlines that were traced manually. The axial images were enhanced on an independent CT scan evaluation console (Siemens Evaluscope RC) using various filters and manipulation of density window widths (i.e., thresholding, to facilitate muscle recognition). Although this process was sufficient to distinguish muscle from fat and bone, we were not able to separate reliably muscle from neural or vascular structures (Fig. 1). Recognition of each independent muscle was achieved by careful observation of perimuscular fat and serial observation of muscle mass; observation moved from unambiguous slices to those with less distinct muscle borders. Each muscle of mastication was manually outlined with an irregular region of interest program.

The muscle volume was calculated by the computer by counting the number of pixels within each outline, converting the pixel count to area (square millimeters), multiplying the surface area by the slice thickness to produce slice volume (cubic millimeters), and then summing the serial volumes to yield the total muscle volume (cubic millimeters). All muscle evaluations were performed by the same investigator. Each muscle volume (i.e., outlining of the muscle surface area on sequential CT slices) was determined three times to assess intraobserver variation. The maximum variation in total muscle volume among each set of three serial determinations was 4 percent. Bilateral assessments of the temporalis, masseter, and medial and lateral pterygoid muscles were obtained. The ratio of the muscle volume found on the clinically affected side divided by that on the clinically unaffected side (affected:unaffected) was expressed as a percentage for each muscle. These muscle volume percentages were compared with mandibular dysmorphology. We operationally defined values of greater than or equal to 75 percent affected:unaffected to be normal and less than 75 percent to be hypoplastic.

Three-dimensional osseous surface reconstructions, right and left lateral and exocranial base images, were used to determine the extent of dysmorphology of the mandibular ramus and body as well as the origins and insertions of the muscles of mastication. Many mandibles were disarticulated to facilitate evaluation. A combination of qualitative and quantitative analyses were utilized to assess the osseous dysmorphology. Qualitative assessments included the size and shape of the mandibular ramus and body as well as that of the medial and lateral pterygoid plates. Tracings of the right and left structures on the three-dimensional osseous surface reformation hard copy were made for each patient. The clinically affected side outline was superimposed on the clinically unaffected side outline, and the degree of dissimilarity between them was rated on a four-part scale for the mandible and a two-part scale for each of the pterygoid plates. Mandibular dysmorphology, in these outlines, was rated using the classification of Pruzansky (1969) as either normal or Pruzansky grade I, II, or III dysmorphic (Fig. 2). Because of the small size of the pterygoid plates, their dysmorphology was rated as either normal (affected size and shape equivalent to unaffected) or hypoplastic. These qualitative assessments were made initially by one author (DB) and then reviewed and a consensus opinion generated by him and one of the other authors (JLM or MWV).

Quantitative measurements were made on the three-dimensional osseous surface reconstructions of mandibular

condylar height, mandibular coronoid process height, and zygoma-zygomatic arch length. Each clinically affected side measurement was divided by its paired clinically unaffected side measurement. These ratios were classified into quartiles (affected:unaffected being (1) greater than or equal to 75 percent; (2) between 74 to 50 percent; (3) between 49 to 25 percent; and (4) less than 25 percent).

RESULTS

Muscle Volume and Mandibular Dysmorphology

All patients had some dysmorphology (altered size, shape, or both) of the hemimandible ipsilateral to the clinically affected side of their face as compared with that of the clinically unaffected side. Using Pruzansky's classification, 14 patients had grade I dysmorphology, seven had grade II, and three had grade III.

The volume of individual muscles of mastication, expressed as the affected side as a percentage of the unaffected, ranged from zero to 141 percent (Tables 1-4). Because of the small number of patients with grade III mandibles, the sets of patients with grade II and III were combined for statistical analysis (Student's *t* test). For each of the four muscles of mastication evaluated, there was a statistically significant difference ($p < 0.002$) between the mean volumes of the muscle for patients with minimal mandibular dysmorphology (Pruzansky grade I) and those with moderate and severe dysmorphology (Pruzansky grade II and III). There was marked variability in the extent of muscle hypoplasia among the patients having similar mandibular dysmorphology. Nonetheless, the more extensive grades of osseous dysmorphology (II and III) were associated with moderate to severe muscular hypoplasia, while the muscle volumes were approximately equal bilaterally for the minimally hypoplastic mandibles (Fig. 3).

Muscle Volume and Hypoplasia of the Muscle's Osseous Origin and Insertion

To facilitate comparisons between a muscle's volume and the osseous dysmorphology of its origin and insertion, the volumes were enumerated according to the affected:unaffected side ratio (i.e., greater than or equal to 75 percent, between 75 and 25 percent, and less than or equal to 25 percent). For the osseous origins and insertions of the muscles of mastication, excepting the pterygoid plates, the affected:unaffected ratio was labelled "normal" when greater than or equal to 75 percent, "hypoplastic" when less than 75 percent but greater than 25 percent, and "aplastic" when less than or equal to 25 percent or less. Because of their small size, the pterygoid plates were classified "normal" for ratios 75 percent or greater and "hypoplastic" for those less than 75 percent.

Muscle volume was directly correlated with bone mass for the following pairs: temporalis muscle-coronoid process (Fig. 4A), lateral pterygoid muscle-condyle (Fig. 4B), lateral pterygoid muscle-lateral pterygoid plate (Fig. 4C), medial pterygoid muscle-lateral pterygoid plate (Fig. 4D), medial pterygoid muscle-medial pterygoid plate (Fig. 4E), and masseter muscle-zygoma/zygomatic arch (Fig. 4F). In contrast, bone mass and muscle volume did not seem to relate

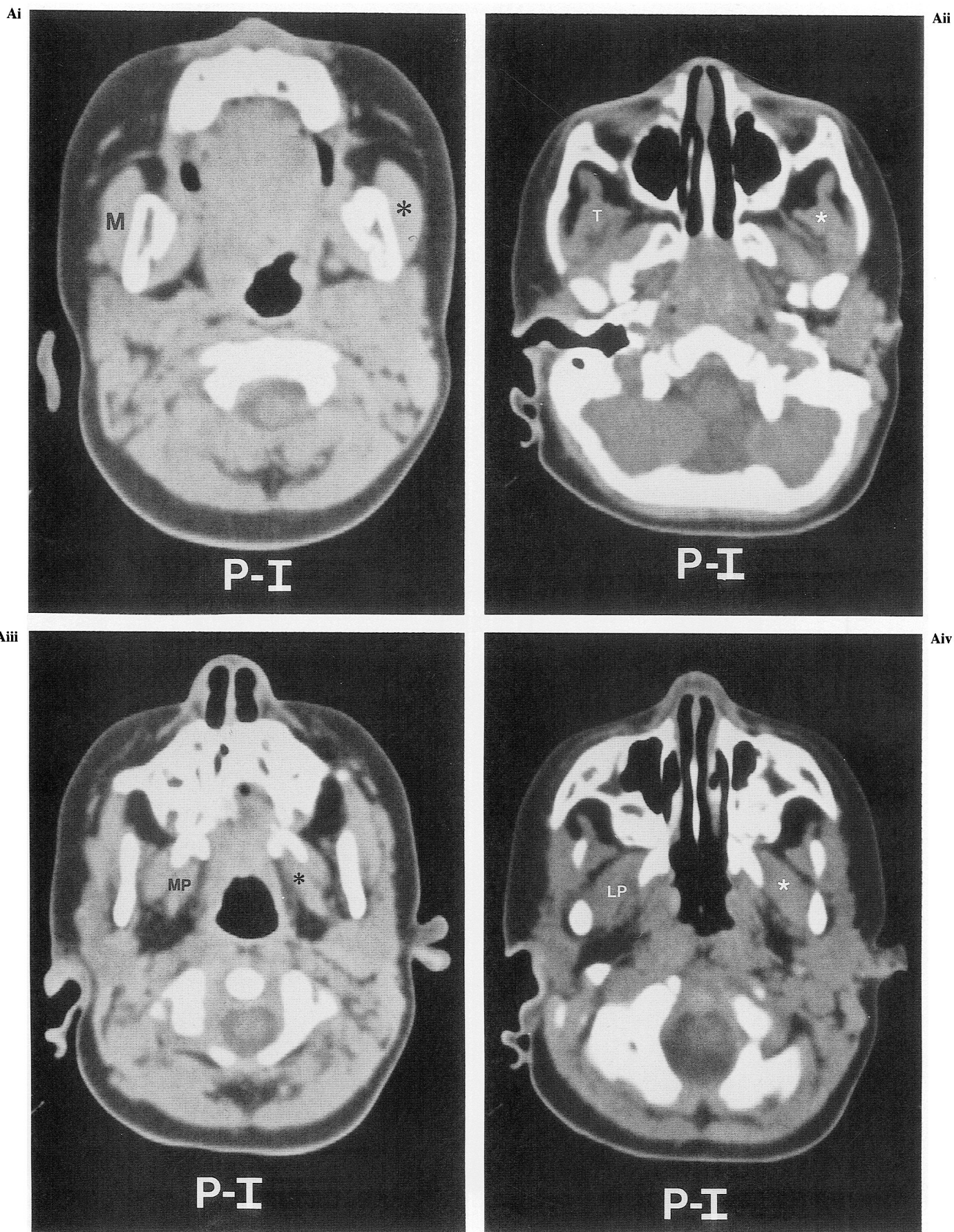


FIGURE 1 Examples of muscles of mastication on axial CT images. The muscle on the clinically affected side is indicated by an asterisk. The muscle on the clinically unaffected side is indicated by the initial(s) of the muscle: M = masseter; T = temporalis; MP = medial pterygoid; LP = lateral pterygoid. A, 17-month-old male with right unilateral hemifacial microsomia having Pruzansky grade I mandibular dysmorphology (see Fig. 2A). (i), Masseter muscle; (ii), temporalis muscle; (iii), medial pterygoid muscle; (iv), lateral pterygoid muscle.

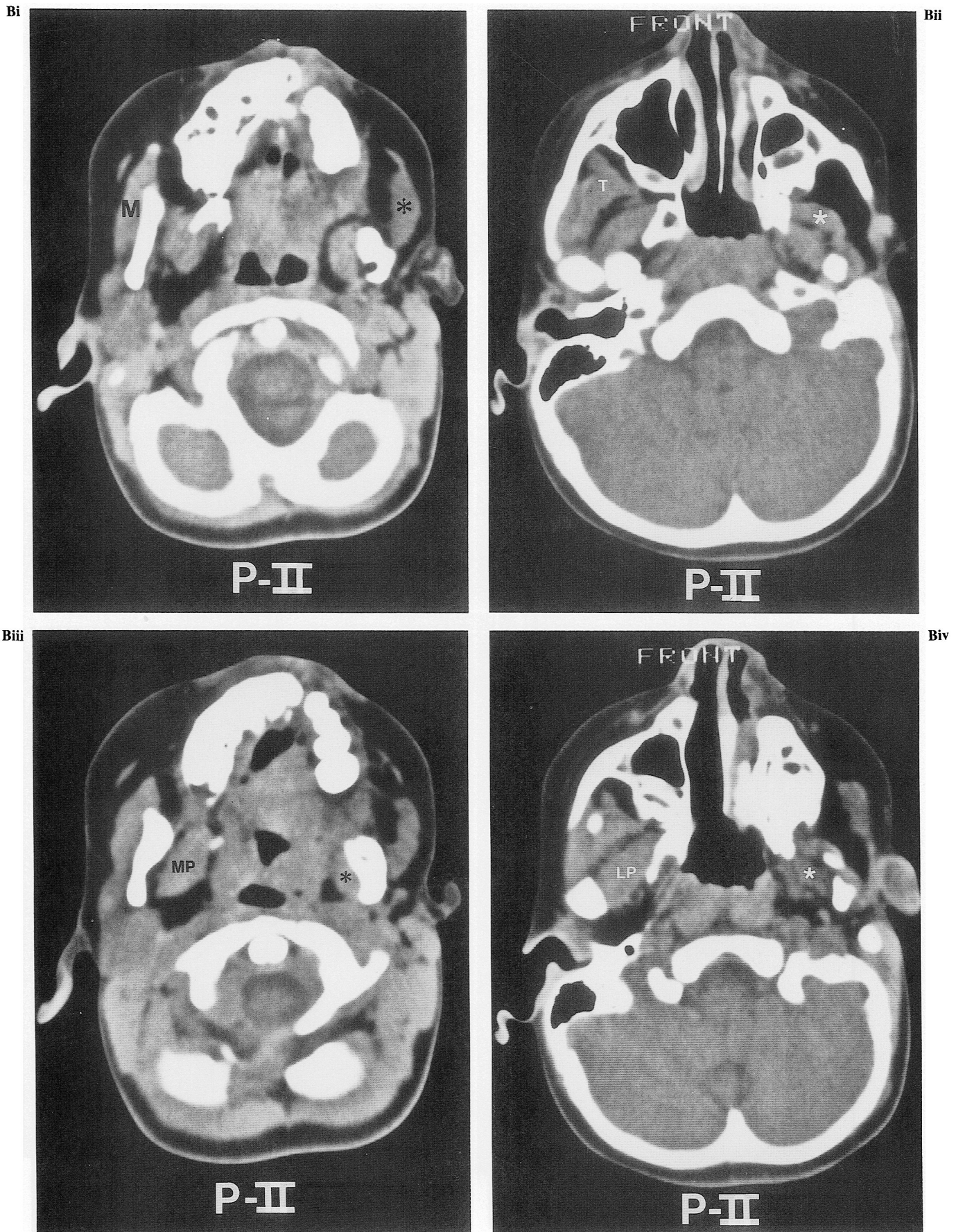


FIGURE 1— Continued. B, 4-year-old female with right unilateral hemifacial microsomia having Pruzansky grade II mandibular dysmorphism (see Fig. 2B). She was also born with a complete right unilateral cleft lip and palate. (i), Masseter muscle; (ii), temporalis muscle; (iii), medial pterygoid muscle; (iv), lateral pterygoid muscle.

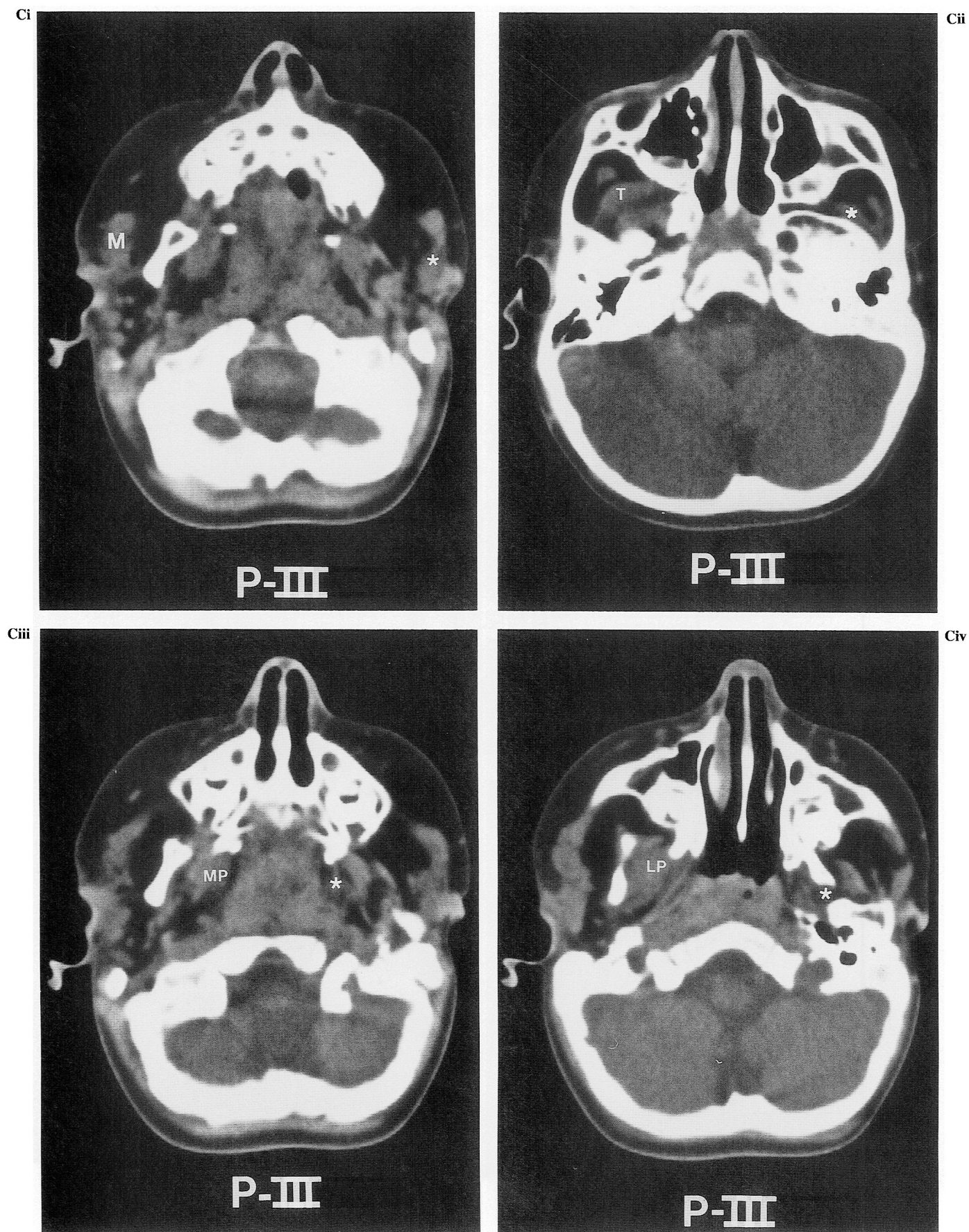


FIGURE 1— Continued. C, 19-month-old male with right unilateral hemifacial microsomia having Pruzansky grade III mandibular dysmorphology (see Fig. 2C). (i), Masseter muscle; (ii), temporalis muscle; (iii), medial pterygoid muscle; (iv), lateral pterygoid muscle.

for the following pairs: medial pterygoid muscle–ramus (Fig. 4G) and masseter muscle–ramus (Fig. 4H).

The individual data on the muscles of mastication were consolidated to express muscle volume as a function of the bone mass of either the muscle's origin or insertion. For origin bone mass, 79 percent of patients with equivalent muscle volume had normal bone mass. Conversely, only 29 percent of patients with hypoplastic muscle volume had normal bone mass. For insertion bone mass, almost half (44 percent) of the patients with normal muscle volume had osseous hypoplasia. The direct relationship between muscle volume and bone mass was most evident for the osseous insertions of those patients with hypoplastic muscle volume. Of these, 91 percent had hypoplastic insertion bone mass.

DISCUSSION

Methodology

In vivo measurement of cavitory and tissue volumes became possible with the advent of CT scanning. In 1978, both Penn et al and Pentlow et al independently reported the calculation of intracranial ventricular volumes from CT scans. Heymsfield et al (1979) addressed the issue of accuracy of volume determinations from CT scans from cadaver solid organs (the liver, kidney, and spleen). Paper templates were traced from serial scan images, and then cut out, weighed, and compared with harvested organ volume as determined by water displacement. The calculated volumes were within 5 percent of those directly measured. This methodology was extended digitally to in vivo evaluations of canine liver, kidney, and spleen by Moss et al (1981), who used a hand-operated cursor to outline irregular "regions of interest." Computer software determined the surface area within the outlines, converted the area to volume for each CT slice image, and summed the slice volumes for a total volume. The regions of interest were outlined twice and the resultant muscle volumes averaged. The calculations were validated by postmortem direct measurement of organ volume by water displacement. The calculated volumes were within 7.5 percent of those directly measured. A similar study by Brenner et al (1982) obtained calculated volumes within 10 percent of water displacement volumes.

Autopsy-validated in vivo calculations of muscle volumes are yet to be reported. Validation of extraocular muscle and orbital volumes was attempted by Forbes et al (1983, 1985), who used two generations of phantom orbits. Volume errors in these phantom studies were approximately 7 to 8 percent. They attributed the error to observer variation, limited soft tissue discrimination in CT scans, and partial volume effects.

A major source of error in our data could come from muscular asymmetry. In those patients with marked muscular hypoplasia, the diminished cross-sectional area and less distinct perimuscular fat of the affected side made outlining more difficult. The asymmetry between paired muscles could influence manual boundary determination. Errors resulting from limitations in tissue density discrimination and the partial volume effects of CT scanning are proportionately larger in hypoplastic muscle regions. Three volume calculations were performed in each case, and they

agreed within 4 percent. An additional source of error could arise from nonhomogeneity of the muscles. Whether the muscles of mastication are of equal composition (percentage of muscle, fat, vessels, nerves, connective tissue) on the affected and unaffected sides is unknown. Consideration also must be given to the assignment of the labels "affected" and "unaffected." Although all patients had unilateral hemifacial microsomia clinically, we recognize that supposedly "unilaterally" affected patients often actually have bilateral anomalies (Converse et al, 1974; Ross, 1975; Farkas et al, 1977). "Less affected" or "clinically unaffected" might be better descriptors of the seemingly normal side. Nonetheless, the comparative assessment of muscle and bone volumes does quantify the expected asymmetry in a reproduction fashion. Since normative muscle volume data for children are unavailable, we cannot assess the normality of the unaffected side in this study.

Findings

The morphologic relationship between bone and its soft tissue environment has been the subject of conjecture, investigation, and debate since at least the late nineteenth century (Wolff, 1892). A hypothetic relationship that emphasizes the primacy of a bone's soft tissue milieu upon its morphology has been most succinctly expressed as the "functional matrix" theory of Moss (1960). This hypothesis has been tested in animal models by studying the effect of muscle ablation, muscle force redirection, and alteration of the upper airway or of mastication on the gross anatomy of the mandible (Pratt, 1943; Washburn, 1947; Horowitz and Shapiro, 1955; Rogers, 1958; Avis, 1959; Moore, 1965; Moss and Meehan, 1970; Harvold et al, 1973; McNamara, 1973; Simon and Moss, 1973; Tomer and Harvold, 1982). In these studies, alteration of the muscles of mastication induced changes in the morphology of the underlying bone. The functional matrix hypothesis and the experiments conducted to test it are the basis for the assertions, made by multiple authors, that there is a direct relationship between the neuromuscular status of the muscles of mastication and the skeletal dysmorphology in patients with hemifacial microsomia (Converse et al, 1973; Ricketts, 1975; Figueroa and Pruzansky, 1982; Harvold, 1983; Vargervik et al, 1986). To examine these assertions, the neuromuscular status of the muscles of mastication and the morphology of the mandible must be known. The latter is best defined to date.

The mandibular dysmorphology of hemifacial microsomia is best known from in vivo x-ray imaging (Pruzansky, 1969; Coccato et al, 1975). Direct examination of museum specimens of hemifacial microsomia skulls (Obwegeser, 1974), which are few in number because of the general nonlethality of the anomaly, and intraoperative observations (Murray et al, 1984) augment the radiographic findings. Cephalometric radiographs are readily available, inexpensive, of minimal morbidity, and can be analyzed against normative data (cephalometric norms). Such imaging has proved the basis for a number of classification schemes for patients with hemifacial microsomia based primarily on mandibular dysmorphology (Swanson and Murray, 1978; Kaban et al, 1981; Vargervik and Miller, 1984), mandibular dysmorphology in conjunction with auricular dysmorphol-

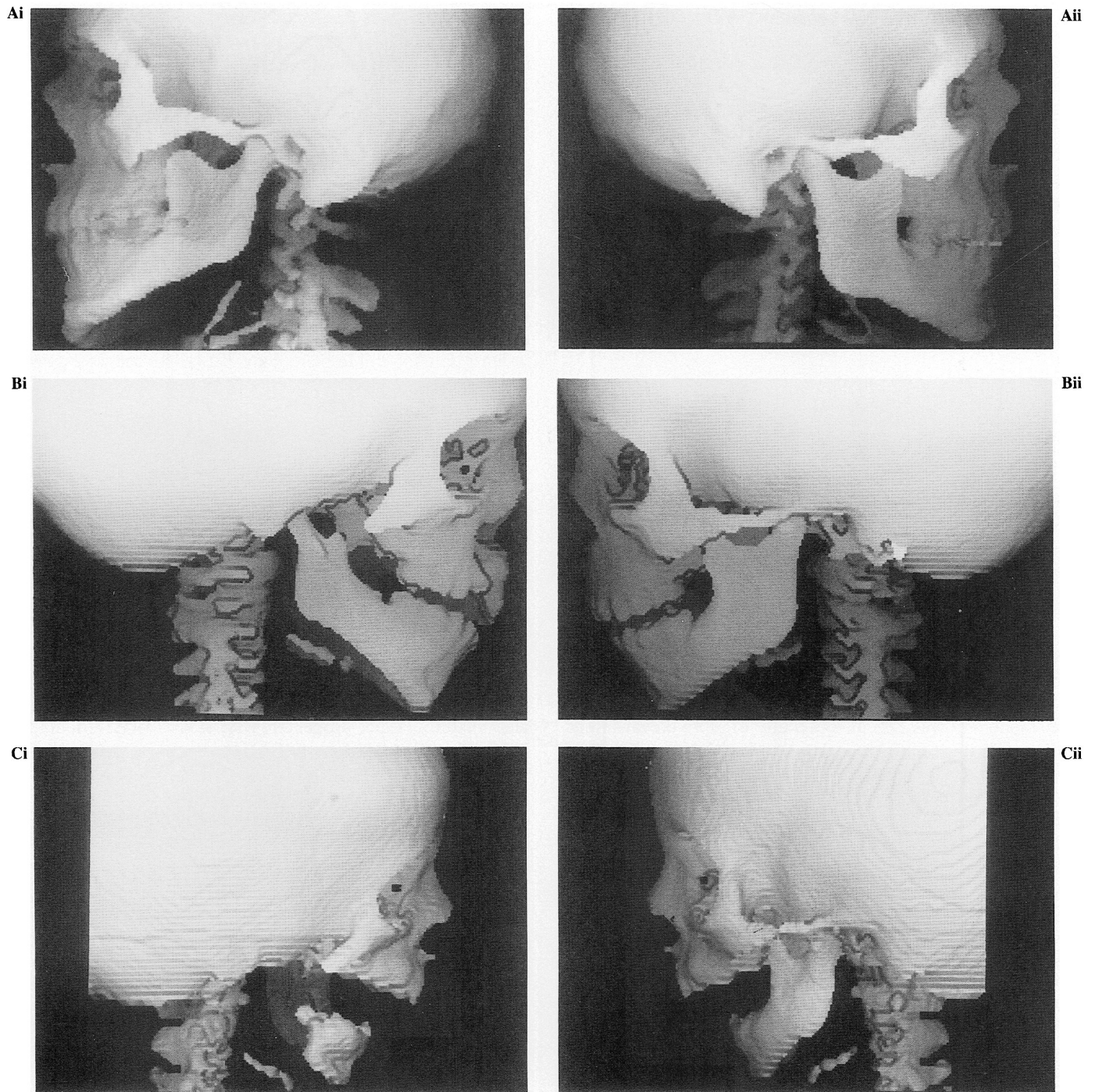


FIGURE 2 Examples of Pruzansky (1969) classification of mandibular dysmorphology. Images are lateral surface shaded osseous reconstructions from CT scan, method Vannier-Marsh (Marsh and Vannier, 1988; Vannier et al, 1988). **A**, 17-year-old male with left unilateral hemifacial microsomia having Pruzansky grade I mandibular dysmorphology. (i), Clinically affected side. The salient features of Pruzansky grade I are the relatively normal shape and reduced size of the affected hemimandible. Comparison with the unaffected side demonstrates hypoplasia of the body of the zygoma, elevation of the zygomatic arch, broadening of the mandibular coronoid process, reduction in the height of the mandibular ramus, and hypoplasia and lateral deviation of the inferior body of the mandible. The stylohyoid ligament is partially calcified on the affected side. (ii), Clinically unaffected side. **B**, 4-year-old female with right unilateral hemifacial microsomia having Pruzansky grade II mandibular dysmorphology. Same patient as Figure 1B. (i), Clinically affected side. The salient features for Pruzansky grade II are the mildly dysmorphic shape and reduced size of the affected hemimandible. Comparison with the unaffected side demonstrates hypoplasia of the body of the zygoma, hypoplasia of the temporal process of the zygoma, aplasia of the zygomatic process of the temporal bone, hypoplasia of the mandibular coronoid process, reduction in height and width of the mandibular ramus, hypoplasia and lateral deviation of the inferior body of the mandible. (ii), Clinically unaffected side. **C**, 3-month-old male with right unilateral hemifacial microsomia having Pruzansky grade III mandibular dysmorphology. (i), Clinically affected side. The salient features for Pruzansky grade III are the markedly dysmorphic shape and reduced size of the affected hemimandible. Comparison with the unaffected side demonstrates hypoplasia of the body of the zygoma; dysmorphology of the temporal process of the zygoma; aplasia of the zygomatic process of the temporal bone; aplasia of the mandibular condyle, coronoid process and ramus; hypoplasia of the mandibular body; and absence of the external auditory meatus. (ii), Clinically unaffected side.

TABLE 1 Masseter Volume* as a Function of Mandibular Dysmorphology

Mandible Dysmorphology	Pruzansky Grades		
	I	II	III
Mean	89.3	36.8	55.5
Median	88.5	23.2	69.1
Standard deviation	24.8	34.2	24.2
Range	48.6–154.6	0.0–92.8	27.5–69.8

* Percent affected side:unaffected side

ogy (Converse et al, 1973; Figueroa and Pruzansky, 1982), the dysmorphology of the entire skull (Munro, 1980; Lauritzen et al, 1985), or a combination of skull dysmorphology and soft tissue anomalies (Grabb, 1965; Edgerton and Marsh, 1977; Vento and Mulliken, 1988).

The neuromuscular status of the muscles of mastication in patients with hemifacial microsomia is less well documented than is the dysmorphology of their mandibles. Several authors have commented upon hypoplasia and aplasia of specific muscles in such patients without clarification of the anatomic source for their statements (Converse et al, 1973; Obwegeser, 1974; Figueroa and Pruzansky, 1982; Mulliken and Kaban, 1987). Using clinical palpation, Grabb (1965) reported an average reduction in masseter bulk in patients with hemifacial microsomia to half of that palpable in normal patients. He also reported "underdevelopment and paresis" of the temporalis without commentary regarding magnitude or frequency of involvement. Murray et al (1984) reported, from intraoperative observations, that "all muscles of mastication are underdeveloped or absent" in their most severely affected patients and that these patients have "a conglomerate muscle mass that seems to contain elements of temporalis, masseter, and pterygoid muscles." They were able to identify muscles of mastication individually in their least affected patients, although they described these muscles as "small." Although inspection of the temporalis and masseter from origin to insertion is compatible with surgical exposure, it is not clear how the origins of the pterygoids were assessed and whether the contralateral "unaffected" muscles were dissected to substantiate comparative statements by these authors. Objective electromyographic (EMG) data concerning function of the temporalis and masseter muscles in patients with hemifacial microsomia were reported by Vargervik and Miller (1984). They contrasted the EMG findings from the affected and unaffected sides of their patients and compared the data with those obtained from nondysmorphic controls.

TABLE 2 Medial Pterygoid Volume* as a Function of Mandibular Dysmorphology

Mandible Dysmorphology	Pruzansky Grades		
	I	II	III
Mean	85.8	56.5	45.7
Median	82.6	61.1	56.7
Standard deviation	12.2	28.6	41.4
Range	70.1–98.9	3.0–99.3	0.0–80.5

* Percent affected side:unaffected side

TABLE 3 Lateral Pterygoid Volume* as a Function of Mandibular Dysmorphology

Mandible Dysmorphology	Pruzansky Grades		
	I	II	III
Mean	98.2	57.1	47.3
Median	96.3	53.5	44.7
Standard deviation	18.0	18.7	20.7
Range	78.5–140.6	32.5–87.3	28.0–69.2

* Percent affected side:unaffected side

They concluded that the "masticatory muscles could demonstrate abnormal recruitment patterns in any type of malformation (degree of mandibular dysmorphology) and also on the relatively intact side."

The relationship between the dysmorphology of the muscles of mastication and that of the mandible has been speculated, as well as definitively commented, on by several authors. Converse et al (1973) stated that "there is a muscular hypoplasia which involves powerful muscles such as the masseter, medial and lateral pterygoid and temporalis and this undoubtedly influences skeletal development." They stated that "when there is condylar hypoplasia or agenesis, the lateral pterygoid muscle on that side is often totally absent. In many cases, the coronoid process is not present, nor is there any evidence of a temporal muscle tendon." Figueroa and Pruzansky (1982) concluded that "there is a direct relationship between the mandibular de-

TABLE 4 Temporalis Volume* as a Function of Mandibular Dysmorphology

Mandible Dysmorphology	Pruzansky Grades		
	I	II	III
Mean	80.1	47.4	52.9
Median	84.2	44.6	78.5
Standard deviation	13.7	21.7	45.8
Range	56.6–96.3	21.9–82.2	0.0–80.2

* Percent affected side:unaffected side

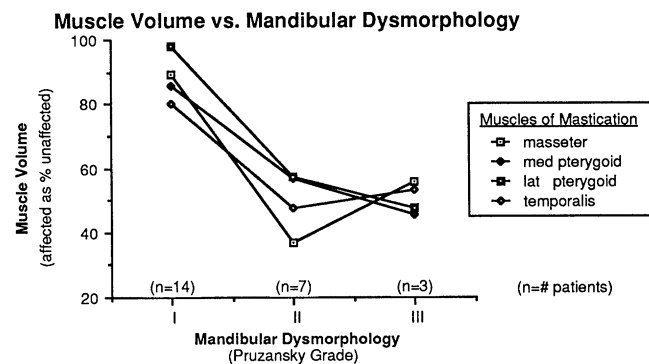


FIGURE 3 Muscle of mastication volume versus mandibular dysmorphology. The muscle volumes are means expressed as clinically affected side:unaffected side percentage. The mandibular dysmorphology grading is that of Pruzansky (1969). For each individual muscle of mastication, there is a statistically significant difference ($p < 0.0002$, Student's t test) between the grade I and the combined grades II and III mean values.

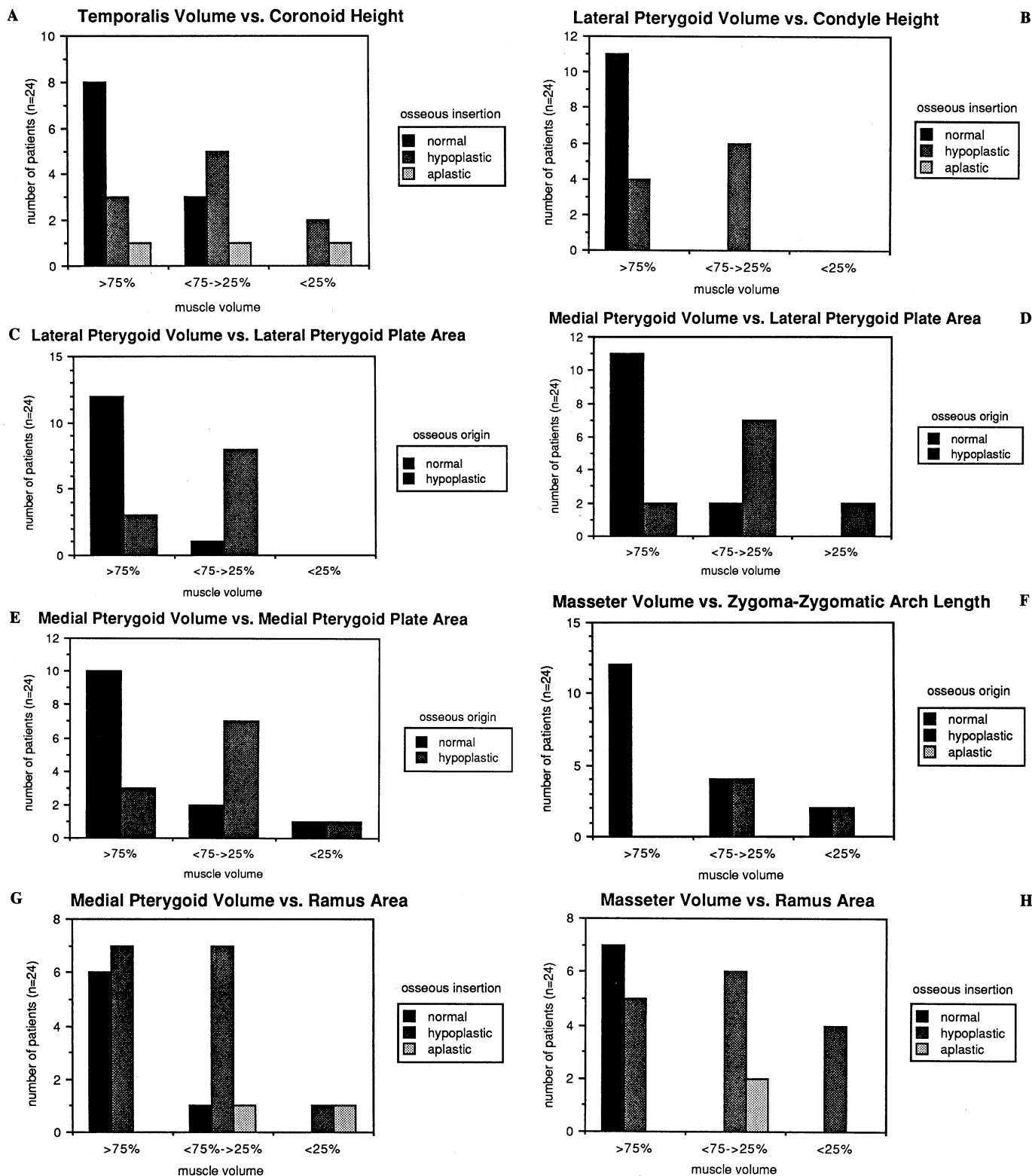


FIGURE 4 Muscle of mastication volume versus the muscle's origin and insertion bone mass. The muscle volumes have been consolidated into three groups based on the percentage of clinically affected side:unaffected side volumes (i.e., ≥ 75 percent, $<75\text{--}\geq 25$ percent, and <25 percent). The bone mass data have been consolidated into either three or two groups. The three groups apply to assessments of the mandibular coronoid process, condyle, and ramus. The data for these bones are quantitative. These three groups are normal (≥ 75 percent affected:unaffected), hypoplastic ($<75\text{--}\geq 25$ percent), and aplastic (<25 percent). Because of their small size, the pterygoid plates are expressed as two groups, i.e., normal (≥ 75 percent affected:unaffected) and hypoplastic (<75 percent). The data for the pterygoid plates are qualitative. A, Temporalis muscle volume versus mandibular coronoid process height. B, Lateral pterygoid muscle versus mandibular condyle height. C, Lateral pterygoid muscle versus lateral pterygoid plate mass. D, Medial pterygoid muscle versus lateral pterygoid plate mass. E, Medial pterygoid muscle versus medial pterygoid plate mass. F, Masseter muscle versus zygoma-zygomatic arch length. G, Medial pterygoid muscle versus mandibular ramus lateral surface area. H, Masseter muscle versus mandibular ramus lateral surface area.

formity and the status of the muscles of mastication." Mulliken and Kaban (1987) reported that "hypoplasia of the lateral pterygoid muscle causes the mandible to deviate toward the affected side of the patient during (oral) opening." None of these authors defined their source of data regarding the muscles of mastication. The objective EMG data concerning function of the temporalis and masseter muscles in patients with hemifacial microsomia reported by Vargervik and Miller (1984) documented masseter activity, albeit abnormal, in the absence of the gonial angle and temporalis activity in the absence of the coronoid process.

The data acquired in this study show variability in the relationship between muscle volume and the shape and size of the muscle's osseous origin and insertion. This variability is present among the specific muscles of mastication as well as among individuals with similar mandibular dysmorphology. Although previous investigators have qualitatively suggested muscle-bone nonuniformity in patients with hemifacial microsomia, only the EMG study of Vargervik and Miller (1984) provided quantification prior to this report. Awareness of this variability is important if the therapeutic approach is based on the premise that the integrity of the functional matrix is essential to management. The status of the muscles of mastication in an individual patient with unilateral hemifacial microsomia cannot be assumed from the degree of osseous dysmorphology visualized on a conventional skull radiograph.

Our consolidated data, however, generally support the hypothesis that the shape and size of the bones of the skull are dependent on the muscles that originate and insert upon them. This seems to be the case for the mandibular condyle and coronoid process, the medial and lateral pterygoid plates, and the zygoma-zygomatic arch. In contrast, the lack of direct correlation between the area of the mandibular ramus and the volume of both the masseter and medial pterygoid muscles argues against the validity of the functional matrix hypothesis. One can postulate that the dysmorphology of the mandibular ramus in hemifacial microsomia is independent of its soft tissue milieu. The dysmorphology may be a direct result of the genome or dependent on functional factors other than the muscles of mastication; alternatively, it may be the result of an interplay between primary osseous and soft tissue deficiencies (Poswillo, 1974).

CONCLUSION

Computer-assisted medical imaging (i.e., transaxial CT scans and three-dimensional surface reconstructions) is an effective means of assessing muscle volume and osseous shape and size in vivo. Application of this technology to 24 patients with unilateral hemifacial microsomia demonstrates that the relationship between the volume of a muscle of mastication and the shape and size of its osseous origin and insertion in such patients varies widely. This variation is present among specific muscles in a given individual and for the same muscle among individuals. Therefore, assumptions regarding muscle mass and, in turn, function cannot be made regarding an individual patient on the basis of osseous dysmorphology that has been demonstrated on skull radiographs alone.

Comparison of mean volumes of specific muscles docu-

ments a statistically significant decrease among patients having moderate to marked mandibular dysmorphology as compared with those having minimally dysmorphic mandibles. This correlation is valid for the masseter, temporalis, and medial and lateral pterygoid muscles. Reductions in the height of the mandibular coronoid and condyle, the area of the medial and lateral pterygoid plates, and the length of the zygoma-zygomatic arch generally parallel reductions in the volume of the muscles that originate or insert upon these osseous features. In contrast, the area of the mandibular ramus appears independent of the volume of both the masseter and medial pterygoid muscles.

This study supports the hypothesis that the shape and size of the mandible are related to the muscles that originate and insert upon it. The variation among individual patients suggests that functional forces beyond the muscles of mastication may be responsible for mandibular dysmorphology in some individuals, that the dysmorphology of the mandible is independent of its functional matrix (e.g., a product of the genome), or that the dysmorphology is the result of an interplay between primary osseous and soft tissue deficiencies.

REFERENCES

- AVIS V. (1959). The relation of the temporal muscle to the form of the coronoid process. *Am J Phys Anthropol* 17:99-104.
- BRENNER DE, WHITLEY NO, HOUK TL, AISNER J, WIERNIK P, WHITLEY J. (1982). Volume determinations in computed tomography. *JAMA* 247:1299-1302.
- COCCARO PJ, BECKER MH, CONVERSE JM. (1975). Clinical and radiographic variations in hemifacial microsomia. *Birth Defects Orig Article Series* 11:314-324.
- CONVERSE JM, COCCARO PJ, BECKER M, WOOD-SMITH D. (1973). On hemifacial microsomia. The first and second branchial arch syndrome. *Plast Reconstr Surg* 51:268-279.
- CONVERSE JM, WOOD-SMITH D, MCCARTHY JG, COCCARO PJ, BECKER MH. (1974). Bilateral hemifacial microsomia. Diagnosis, classification, treatment. *Plast Reconstr Surg* 54:413-423.
- EDGERTON MT, MARSH JL. (1977). Surgical treatment of hemifacial microsomia (first and second branchial arch syndrome). *Plast Reconstr Surg* 59:653-666.
- FARKAS LG, ROSS RB, JANES J. (1977). Anthropometry of the face in lateral facial dysplasia. *Cleft Palate J* 14:41-51.
- FIGUEROA AA, PRUZANSKY S. (1982). The external ear, mandible and other components of hemifacial microsomia. *J Maxillofac Surg* 10:200-211.
- FORBES G, GEHRING DG, GORMAN CA, BRENNAN MD, JACKSON IT. (1985). Volume measurements of normal orbital structures by computed tomographic analysis. *AJNR* 6:419-424.
- FORBES G, GORMAN C, GEHRING D, BAKER HL. (1983). Computer analysis of orbital fat and muscle volumes in Graves ophthalmopathy. *AJNR* 4:737-740.
- GORLIN RJ, PINDBORG JJ. (1964). *Syndromes of the head and neck*. New York: McGraw-Hill, 546-552.
- GRABB WC. (1965). The first and second branchial arch syndrome. *Plast Reconstr Surg* 36:485-506.
- HARVOLD EP. (1983). The theoretical basis for the treatment of hemifacial microsomia. In: Harvold EP, Vargervik K, Chierici G, eds. *Treatment of hemifacial microsomia*. New York: Alan R. Liss, 1-37.
- HARVOLD EP, VARGERVIK K, CHIERICI G. (1973). Primate experiments on oral sensation and dental malocclusions. *Am J Orthodont* 63:494-508.
- HEYMSFIELD SB, FULENWIDER T, NORDLINGER B, BARLOW R, STONES P, KUTNER M. (1979). Accurate measurement of liver, kidney, and spleen volume and mass by computerized axial tomography. *Ann Intern Med* 90:185-187.
- HOROWITZ SL, SHAPIRO HH. (1955). Modification of the skull and jaw architecture following removal of the masseter muscle in the rat. *Am J Phys Anthropol* 13:301-308.
- KABAN LB, MULLIKEN JB, MURRAY JE. (1981). Three-dimensional ap-

- proach to analysis and treatment of hemifacial microsomia. *Cleft Palate J* 18:90-99.
- LAURITZEN C, MUNRO IR, ROSS BR. (1985). Classification and treatment of hemifacial microsomia. *Scand J Plast Reconstr Surg* 19:33-39.
- MARSH JL, VANNIER MW. (1988). Computer-assisted imaging in the diagnosis, management and study of dysmorphic patients. In: Vig KWL, Burdi AR, eds. *Craniofacial morphogenesis and dysmorphogenesis*. Ann Arbor: Center for Human Growth and Development, University of Michigan, 109-126.
- McNAMARA JA. (1973). Neuromuscular and skeletal adaptations to altered function in the orofacial region. *Am J Orthodont* 64:578-606.
- MOORE WJ. (1965). Masticatory function and skull growth. *Zoology* 146: 123-131.
- MOSS AA, FRIEDMAN MA, BRITO AC. (1981). Determination of liver, kidney and spleen volumes by computed tomography: an experimental study in dogs. *J Comput Assist Tomogr* 5:12-14.
- Moss ML. (1960). Functional analysis of human mandibular growth. *J Prosthet Dent* 10:1149-1159.
- Moss ML, MEEHAN MA. (1970). Functional cranial analysis of the coronoid process in the rat. *Acta Anat* 77:11-24.
- MULLIKEN JB, KABAN LB. (1987). Analysis and treatment of hemifacial microsomia in childhood. *Clin Plast Surg* 14:91-100.
- MUNRO IR. (1980). One-stage reconstruction of the temporomandibular joint in hemifacial microsomia. *Plast Reconstr Surg* 66:699-710.
- MURRAY JE, KABAN LB, MULLIKEN JB. (1984). Analysis and treatment of hemifacial microsomia. *Plast Reconstr Surg* 74:186-199.
- OBWEGESER HL. (1974). Correction of the skeletal anomalies of otomandibular dysostosis. *J Maxillofac Surg* 2:73-94.
- PENN RD, BELANGER MG, YASNOFF WA. (1978). Ventricular volume in man computed from CAT scans. *Ann Neurol* 3:216-223.
- PENTLOW KS, ROTTENBERG DA, DECK MDF. (1978). Partial volume summation: a simple approach to ventricular volume determination from CT. *Neuroradiology* 16:130-132.
- Poswillo D. (1974). Otomandibular deformity: pathogenesis as a guide to reconstruction: *J Maxillofac Surg* 2:64-72.
- PRATT LW. (1943). Experimental masseterectomy in the laboratory rat. *J Mammal* 24:204-211.
- PRUZANSKY S. (1969). Not all dwarfed mandibles are alike. *Birth Defects Original Article Series* 1:120-129.
- RICKETTS RM. (1975). Mechanisms of mandibular growth: a series of inquiries on the growth of the mandible. In: McNamara JA, ed. *Determinants of mandibular form and growth*. Ann Arbor: Center for Human Growth and Development, University of Michigan, 77-100.
- ROGERS WM. (1958). The influence of asymmetry of the muscles of mastication upon the bones of the face. *Anat Rec* 131:617-632.
- ROSS RB. (1975). Lateral facial dysplasia (first and second branchial arch syndrome, hemifacial microsomia). *Birth Defects Original Article Series* 11:51-59.
- SIMON M, Moss ML. (1973). Dynamics of sigmoid notch configuration and its relationship to total normal morphology. *Acta Anat* 85:133-144.
- SWANSON LT, MURRAY JE. (1978). Asymmetries of the lower part of the face. In: Whitaker LA, Randall P, eds. *Symposium on reconstruction of jaw deformities*. St. Louis: CV Mosby, 171.
- TOMER BS, HARVOLD EP. (1982). Primate experiments on mandibular growth direction. *Am J Orthodont* 82:114-119.
- VANNIER MW, MARSH JL, BIONDETTI PR, eds. (1988). Three dimensional imaging. *Comput Med Imag Graph* 12:1-83.
- VARGERVIK K, MILLER AJ. (1984). Neuromuscular patterns in hemifacial microsomia. *Am J Orthodont* 86:33-42.
- VARGERVIK K, OUSTERHOUT DK, FARIAS M. (1986). Factors affecting long-term results in hemifacial microsomia. *Cleft Palate J (Suppl)*:53-68.
- VENTO R, MULLIKEN J. (1988). OMENS classification of hemifacial microsomia. Presented at the annual meeting of the American Cleft Palate Association, 29 April, Williamsburg, VA.
- WASHBURN SL. (1947). The relation of the temporal muscle to the form of the skull. *Anat Rec* 99:239-248.
- WOLFF J. (1892). *Gesetz der transformatron der knochen*. Berlin: August Hirschwald.